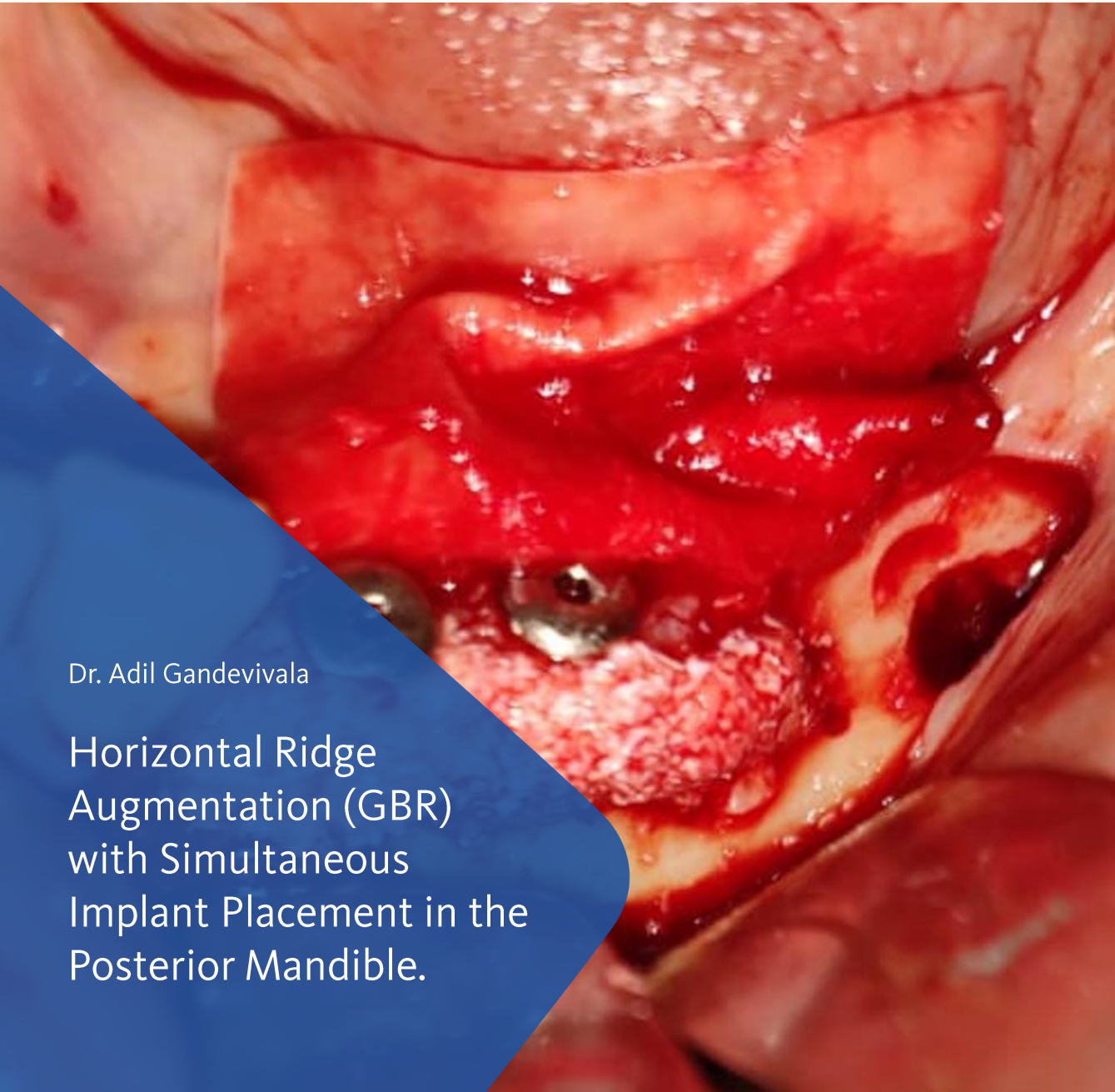


BioBrief

Major Bone Augmentation



Dr. Adil Gandevivala

Horizontal Ridge
Augmentation (GBR)
with Simultaneous
Implant Placement in the
Posterior Mandible.

The Situation

A 70 year old female patient came to us with a complaint of misfitting mandibular dentures. She wanted fixed teeth. She was medically fit and had multiple fixed prosthesis in her dentition. Intraoral examination revealed that she had missing lower left premolars and molars. The site looked resorbed in both the vertical, but more in the horizontal dimension. A knife point edge was palpable on the crest of the edentulous ridge.

The Risk Profile

Risk Factors	Low Risk	Medium Risk	High Risk
Patient's health	Intact immune system	Light smoker	Impaired immune system
Patients esthetic requirements	Low	Medium	High
Height of smile line	Low	Medium	High
Gingival biotype	Thick- "low scalloped"	Medium- "medium scalloped"	Thin- "high scalloped"
Shape of dental crowns	Rectangular		Triangular
Infection at implant site	None	Chronic	Acute
Bone height at adjacent tooth	≤ 5 mm from contact point	5.5 - 6.5 mm from contact point	≥ 7mm from contact point
Restorative status of adjacent tooth	Intact		Restored
Width of tooth gap	1 tooth (≥ 7mm)	1 tooth (≤ 7 mm)	2 teeth or more
Soft tissue anatomy	Intact		Compromised
Bone anatomy of alveolar ridge	No defect	Horizontal defect	Vertical defect

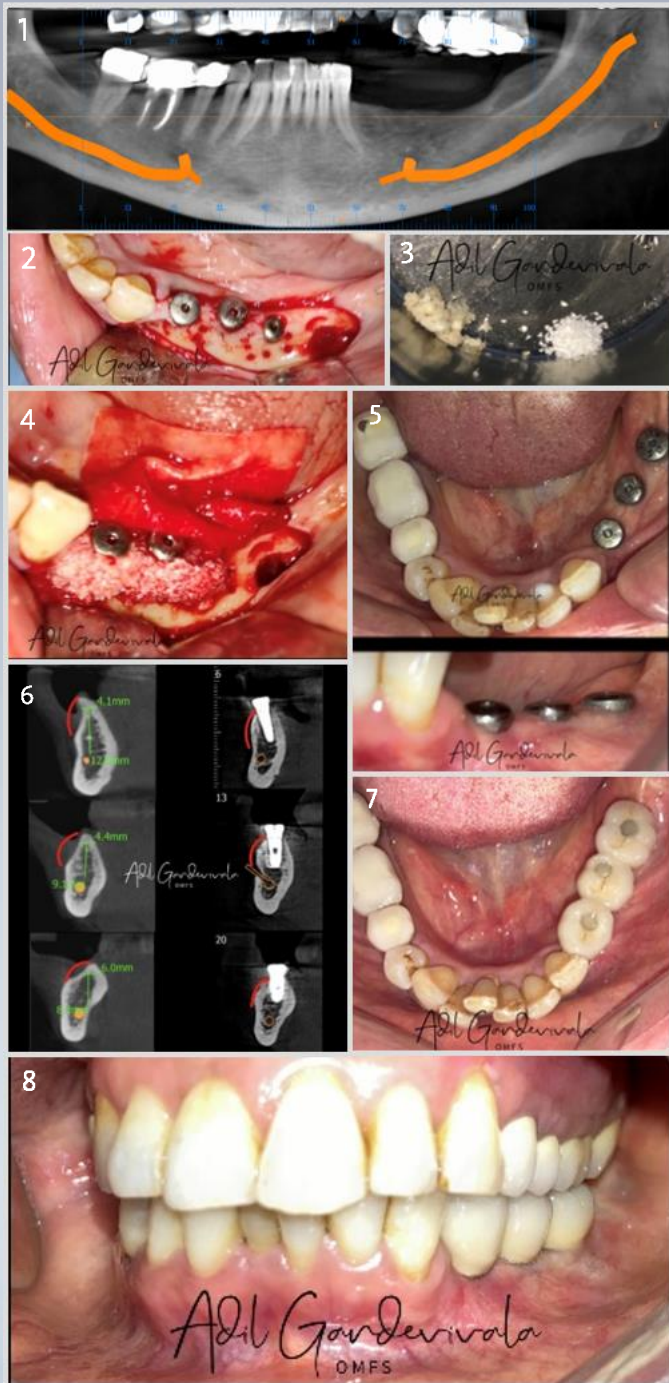
Dr. Adil Gandevala, Mumbai Oral Surgeon

Dr. Gandevala is a MDS in Oral & maxillofacial surgery and FAM Fellowship in Aesthetic Medicine & FISOI- Fellow of Indian Society of Oral Implantologists. He is a Reader/ Associate Professor at MGM Dental College & Hospital, Mumbai.

He is also a consultant with Saifee Hospital Charni Road, Wockhardt Hospital South Mumbai, St Elizabeth's Hospital, Masina Hospital, Hinduja Healthcare Khar and Fortis Vashi.

He specializes in Dentoalveolar surgeries, Advanced implantology, TMJ disorders, Maxillofacial trauma, Orthognathic & Facial Aesthetic surgeries, Benign Maxillofacial pathologies & infections & Oral cancer.





The Approach

A decision was taken to place 3 endosseous dental implants and simultaneously graft the buccal area with the GBR technique.

The patient being older in age wanted the most simple and conservative procedure possible and denied undergoing any soft tissue grafting procedures.

The Outcome

Free Hand Implant placements were done in the region of lower left first premolar, second premolar and first molar.

Autogenous bone chips harvested from ipsilateral ramus by extending the incision.

Geistlich Bio-Gide® was tacked on the lingual aspect.

Similar quantity of Autogenous bone chips & small particle Geistlich Bio-Oss® was mixed and placed on the recipient bed.

The Geistlich Bio-Gide® was then used to cover the graft buccally and was then stabilized using tacs.

Closure was done in 2 layers using 4-0 Monocryl.

1. Pre-operative CBCT.
2. Implants placed & perforations made in buccal cortex.
3. Autogenous bone chips harvested from ipsilateral ramus and mixed with an equal quantity of small particle Geistlich Bio-Oss®.
4. Bone graft placed and Geistlich Bio-Gide® tacked on lingual aspect.
5. Clinical healing after 6 months.
6. Comparison of pre & post CBCT.
7. 1 year Follow up, Occlusal view.
8. 1 year Follow up, Labial view.



More details about our
distribution partners:
www.geistlich-biomaterials.com

Manufacturer

Geistlich Pharma AG
Business Unit Biomaterials
Bahnhofstrasse 40
6110 Wolhusen, Switzerland
Phone +41 41 492 55 55
Fax +41 41 492 56 39
www.geistlich-biomaterials.com

Affiliate India

Geistlich Pharma India Pvt. Ltd.
DSM- 161 & 162, 1st Floor,
DLF Towers, 15 Shivaji Marg,
Main Najafgarh Road,
New Delhi - 110015
India.
Phone : +91 11 4164 1609
info@geistlich.in
www.geistlich.in
www.shop.geistlich.in



Keys to Success

- ✓ Careful flap elevation with adequate release of buccal and lingual flaps to allow tension free closure
- ✓ Mixing of Geistlich Bio-Oss® bone with Autogenous bone in 1:1 ratio
- ✓ Complete stabilisation of bone graft with Geistlich Bio-Gide® and bone tacs
- ✓ Double layered tension free closure



“Ridge augmentation combining the use of Geistlich Bio-Oss® and Geistlich Bio-Gide® is a predictable regenerative procedure able to create sufficient ridge volume suitable for implant placement..”

