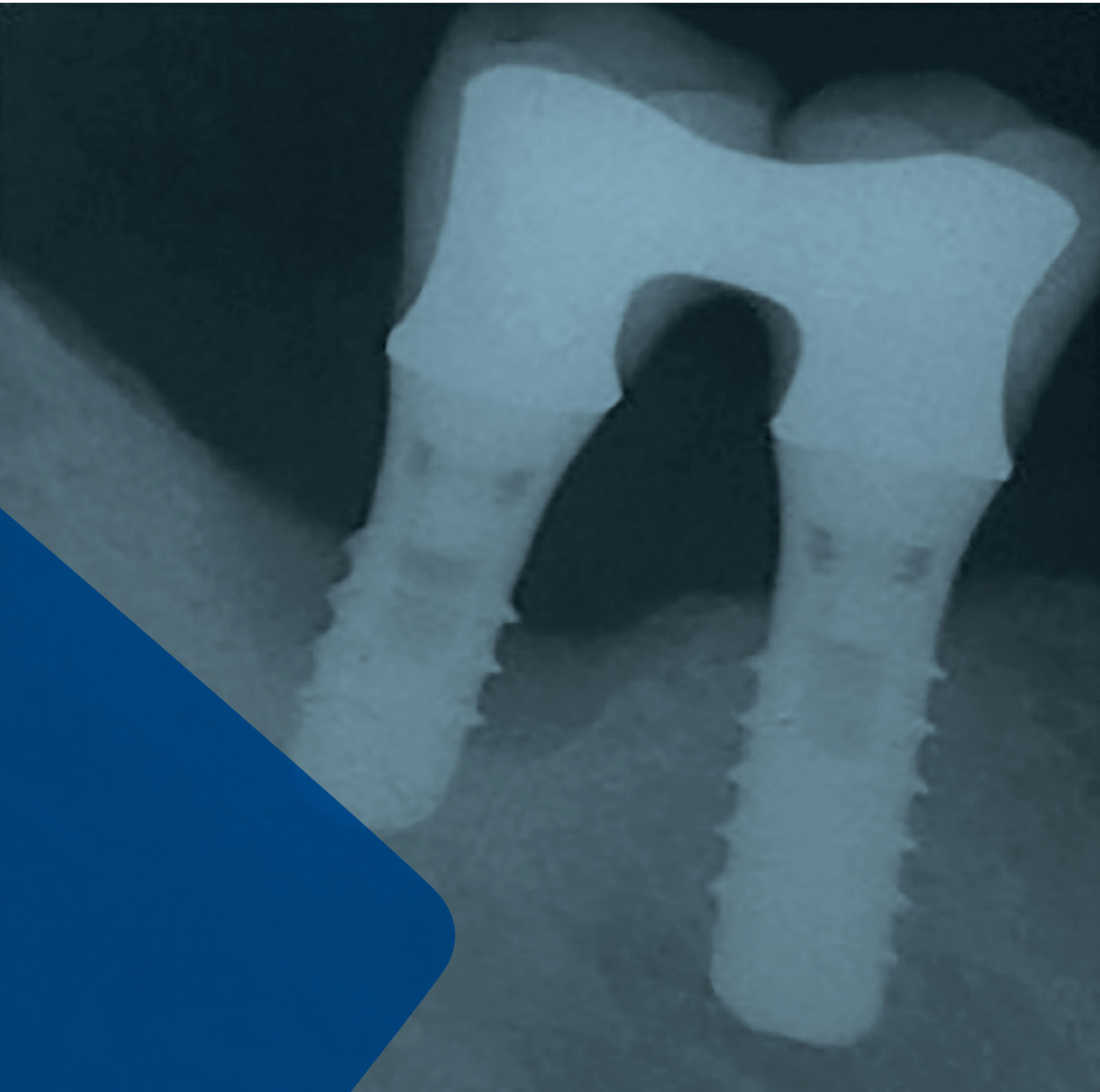


LEADING REGENERATION

Geistlich
Biomaterials

Peri-Implantitis

Treatment Concepts



Content

Definition, diagnosis and prevalence	3
Risk factors and preventive measures	5
Latest evidence on the treatment of peri-implantitis	6

Clinical Cases

Regenerative peri-implantitis treatment (Heitz-Mayfield, Australia)	10
Aesthetic and functional treatment of peri-implantitis (Lee, Korea)	12
Peri-implantitis therapy in the posterior mandible (Stein/Hammächer, Germany)	14
Maintenance of implant in the mandible (McAllister, USA)	16
Implant therapy to restore missing posterior dentition (Norton, United Kingdom)	18
Aesthetic and functional peri-implantitis therapy in the maxilla (Ramel, Switzerland)	20
Regeneration of deep peri-implantitis induced bony defect (Roccuzzo, Italy)	22
Regenerative therapy of peri-implantitis defect in the mandible (Salvi, Switzerland)	24
Regenerative therapy combined with implant plastic surgery (Schwarz, Germany)	26
Regenerative therapy of peri-implantitis in the posterior region (Giovannoli, France)	28
Product range	30
References	31

Definition, Diagnosis and Prevalence

Definitions

Peri-implant disease is a pathological condition around dental implants. The disease ranges from reversible mucositis lesions (reflecting a host's response to bacterial challenge) to non-reversible peri-implantitis, where significant alveolar bone has been lost.¹

PERI-IMPLANT MUCOSITIS

Inflammatory lesion of the peri-implant mucosa with bleeding on probing and/or suppuration, but without bone loss.

PERI-IMPLANTITIS

Inflammatory lesions that include progressive bone loss.

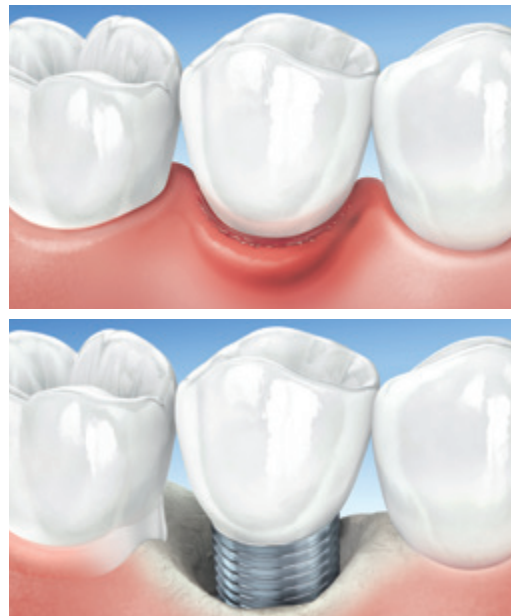

Fig. 1: Visualization of peri-implant mucositis and peri-implantitis.

Diagnosis

The typical symptoms of mucositis and peri-implantitis have been discussed in detail at various consensus conferences²⁻⁸ and can be summarized as follows:



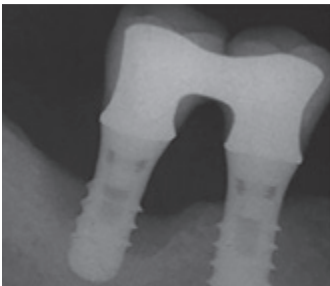

MUCOSITIS Signs and symptoms	PERI-IMPLANTITIS Signs and symptoms		
 <ul style="list-style-type: none"> > Redness and swelling > Bleeding on probing (BOP) > No loss of bone 	 <ul style="list-style-type: none"> > Redness and swelling > Bleeding and/or suppuration upon probing 	 <ul style="list-style-type: none"> > Bone defect with a crater-like shape 	 <ul style="list-style-type: none"> > Progressive bone loss

Fig. 2: Signs and symptoms of peri-implant mucositis and peri-implantitis. (Left picture by courtesy of Dr. Giovannoli; three right pictures by courtesy of Prof. Mombelli)

Implant probing plays a key role in diagnosing peri-implant disease. An increasing probing pocket depth is a likely indicator of the onset of peri-implant disease and should be followed with a radiographic examination for bone loss. Bone changes should be compared with baseline radiographs taken at the time of reconstruction. Formation of pockets, bleeding on probing, suppuration and progressive bone loss are the disease-defining, clinical signs of peri-implantitis.^{2,9}

Prevalence and Epidemiology

To date no specially designed epidemiological study is published to calculate the prevalence of peri-implantitis. The prevalence (occurrence in a population) and incidence (the rate of disease occurrence) can only be calculated from retrospective cohort studies, and the calculated prevalence depends on disease definition. Current studies use heterogeneous definitions for peri-implantitis, and therefore, results are not always comparable.

Nevertheless, based on a recent review article, the prevalence of peri-implantitis after 5–10 years appears to be 10% of implants and 20% of patients (Fig. 3).² Peri-implant mucositis appears to affect approximately 50% of implant sites and 80% of patients.^{8,10} Another publication shows meta-analyses estimated mean prevalences of peri-implant mucositis and peri-implantitis of 43% and 22%, respectively.⁵¹

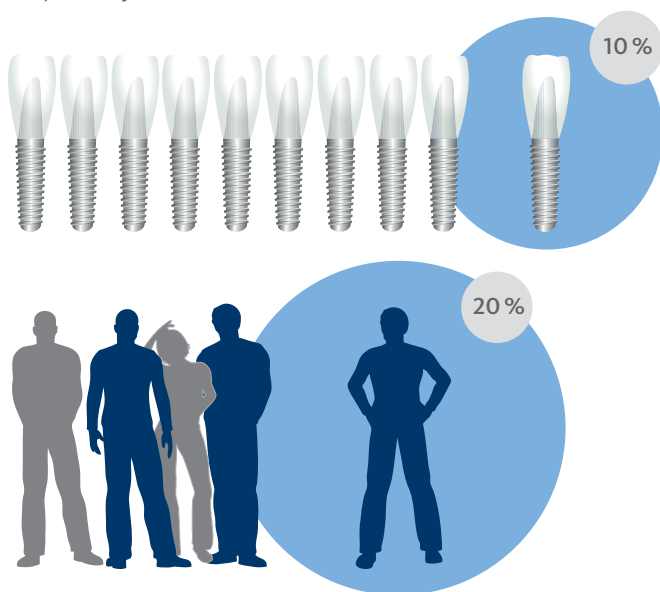


Fig. 3: On average peri-implantitis can occur around every tenth implant and in every fifth patient after a five to ten year period.

PERIO CASE HISTORY

The survival and success rates of implants in patients with previously recorded periodontitis are lower than in patients without periodontal issues¹³.

Conclusion: a check for periodontal infection prior to implantation is highly recommended. Leaving residual pockets > 5 mm with bleeding on probing jeopardizes implant success rate^{14,15}.

SURFACE ROUGHNESS

Implants with a smooth or microrough surface show a comparable incidence of peri-implantitis over a 13-year observation period²⁷.

MUCOSITIS

Diagnosed and untreated mucositis is more likely to develop into peri-implantitis than treated mucositis²⁶.

Conclusion: treat mucositis promptly.

Risk factors and preventive measures:

Risk factors

A number of risk factors have been identified that may lead to the establishment and progression of peri-implant mucositis and peri-implantitis.^{11,12} The risk factors and therapy considerations summarized by Prof. Giovanni Salvi are shown in Fig. 4.

Preventive measures

- > Customize patient's monitoring to his/her needs & control for plaque level and signs of inflammation.
- > Minimize modifiable risk factors as described in Fig. 4.²⁸
- > For high long-term survival of dental implants and their restorations, enrollment in regular supportive periodontal therapy including anti-infective preventive measures should be implemented.⁵²

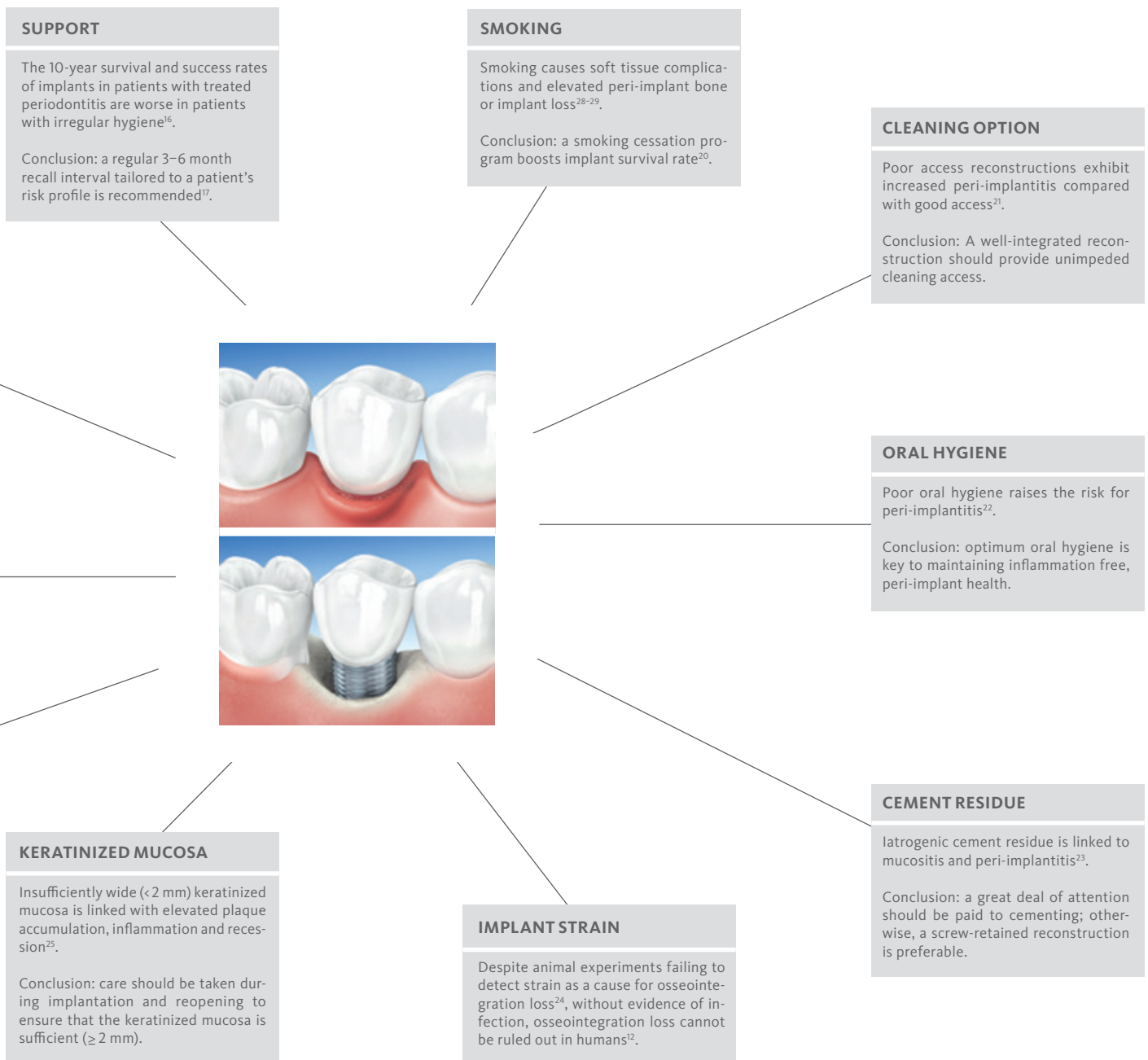


Fig. 4: Risk factors and preventive measures.

Latest evidence on the treatment of peri-implantitis

The principle of peri-implant treatment follows an approach analogous to periodontitis treatment and includes three phases (Fig. 5):

- > systemic phase
- > corrective phase
- > supportive phase⁹

1 Anamnesis/Findings

Usually treatment is started only after consideration of iatrogenic causative factors, such as screw-loosening, excess luting cement, poor abutment fit or poor prosthesis contour. Additional risk factors that might be considered prior to active intervention include:^{29,30}

- > Poor oral hygiene
- > Prostheses that limit access for plaque control
- > Smoking and alcohol consumption
- > Presence of periodontal diseases
- > Systemic diseases (e.g., diabetes) that may predispose peri-implant disease

2 Systemic Phase – Hygiene Phase

The aim of the hygiene phase is to achieve adequate plaque control. The patient should be instructed in good oral hygiene technique.³⁰ Since adequate oral hygiene is often difficult to manage in the peri-implant area due to prosthetic superstructures, customized hygiene according to individual needs is particularly important.⁹ Additionally, in order to prevent disease progression, the pathogenic microflora must be reduced. Depending on access and extent of disease, scaling and root planing may effectively remove bacterial biofilms and calculus from the root surface.⁹

Generally, the corrective phase of the systematic therapy of peri-implant infections should not begin until a stable oral hygiene and plaque index (PI) value of < 1 is achieved.⁹

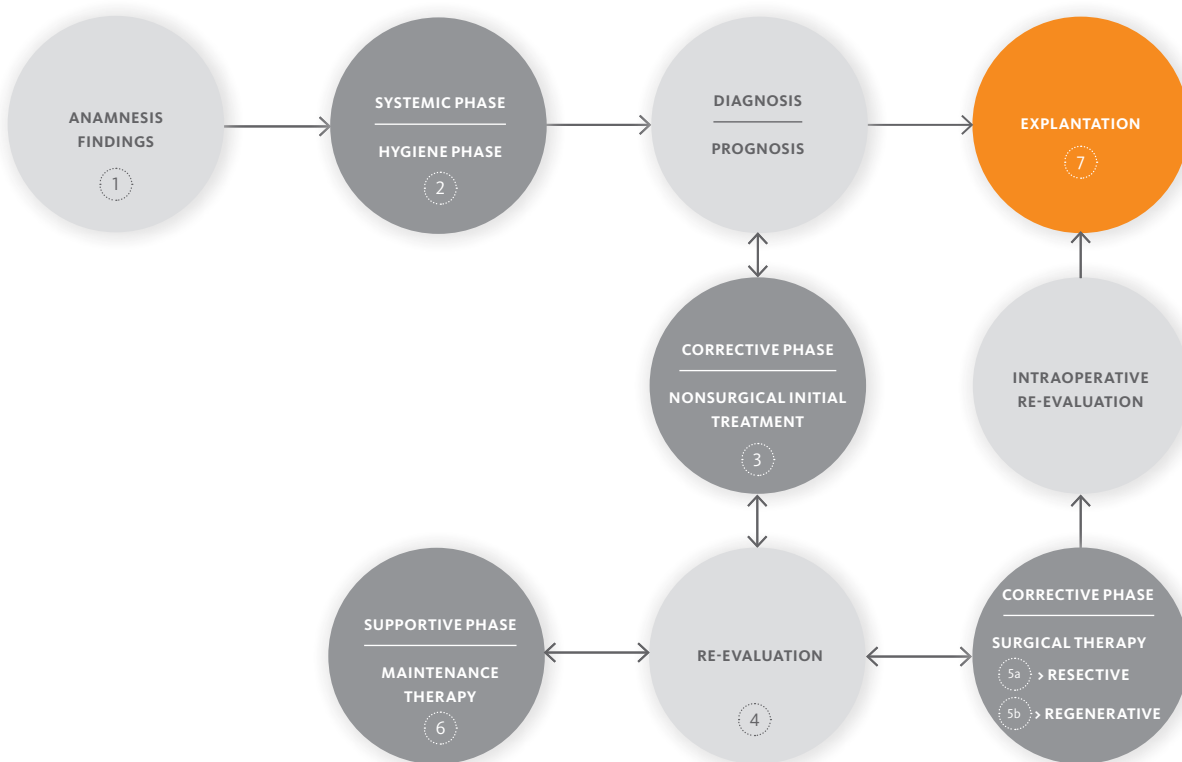


Fig. 5: Decision tree. Adapted from Schwarz F & Becker J, Peri-implant Infection: Etiology, Diagnosis and Treatment.



Prof. Heitz-Mayfield

“Although there are currently no randomized controlled trials evaluating the effect of systemic antimicrobials, peri-operative systemic antimicrobials are commonly prescribed to suppress the microbial load.”

3 Corrective Phase – Non-surgical Treatment

Non-surgical debridement using appropriate instruments, such as plastic, carbon or titanium curettes, air-powder abrasive devices, ultrasonic devices, photodynamic therapy, or Er:YAG laser, can precede surgical intervention.^{9,30} Concomitant therapy with systemic antibiotics, locally delivered antibiotics or the use of topical antiseptics (e.g., chlorhexidine) may be beneficial in reducing both bleeding on probing and pocket depth.^{31,32}

4 Re-evaluation

Early reassessment of peri-implant health is recommended within 1 to 2 months after debridement.³⁰ Some cases of minor peri-implantitis might resolve following nonsurgical management, but in most cases the correction may only halt, or at best, slow disease progression. Depending on the bone defect and the residual osseointegration of the implant, patients might continue maintenance therapy, be candidates for surgical treatment or be considered for explantation.

5 Corrective Phase – Surgical Treatment

If the peri-implantitis has not resolved at re-evaluation, a surgical approach may be recommended. Additionally, since non-surgical

treatment failed to promote the re-osseointegration at exposed implant sites, additional surgical interventions may be required in order to minimize the risk of reinfection of the peri-implant pocket, which might be achieved either by resective surgery or by regenerative bone augmentation procedures.⁹

As a guideline, the initial treatment phase should result in a significant reduction of bleeding on probing scores as well as the absence of suppuration and pus formation. Accordingly, a surgical treatment procedure may not be recommended until this primary objective of treatment is achieved.⁹

The first step and a major objective of the surgical procedure is to provide access for debridement and decontamination of the infected implant surface. Surgical management involves elevation of a full mucoperiosteal flap and elimination of the inflammatory granulation tissue to allow thorough decontamination of the implant surface.³⁰ Biofilm and calculus must be removed to allow healing and reduce the risk for further disease progression or reinfection.³³ The following techniques for implant surface decontamination have been proposed: locally applied chemicals, gauze soaked with saline or antiseptics, hand-powered instruments, air-powder abrasives, Er:YAG lasers, photodynamic therapy, and implant surface modifications (Fig. 6).³⁰

So far, no single method of surface decontamination has been proven to be superior.^{34,35}

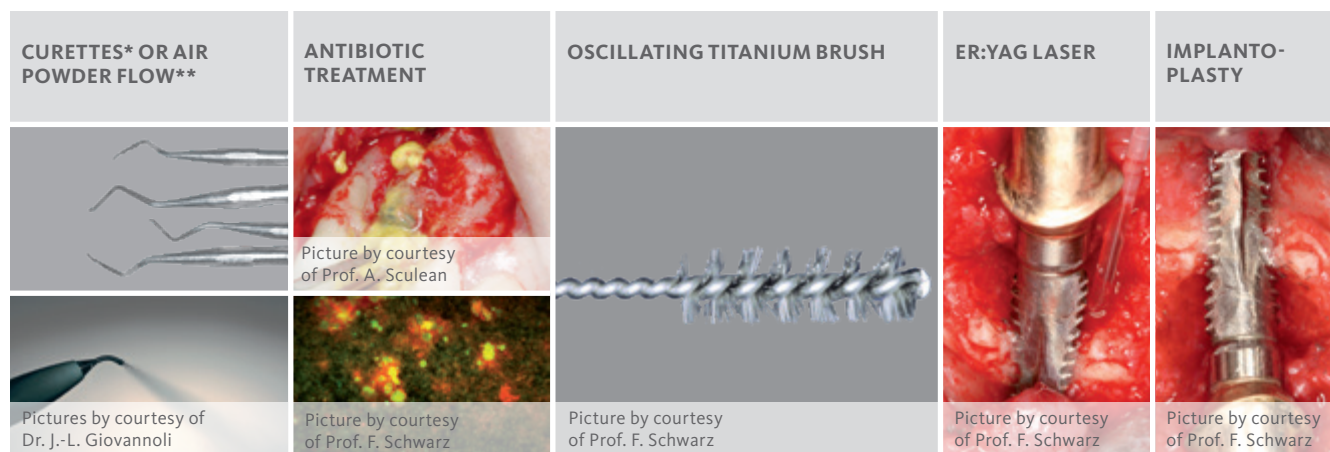


Fig. 6: Techniques for implant surface decontamination

* (e.g. plastic, carbon-fiber)

** (e.g. sodium bicarbonate or glycine powder)

5a Resective approach

The concept of surgical-resective therapy consists of the reduction or elimination of hyperplastic or pathologic peri-implant pockets, which have been resistant to initial treatment and/or have been too difficult to access for good oral hygiene by the patient.⁹ Resective treatment is achieved through osteoplasty to reduce the intrabony defect and through apically repositioning the mucosal margin, thereby reducing the non-accessible surface.³⁶ Furthermore, some clinicians perform implantoplasty, smoothing and polishing all supracrestal or transmucosal implant surfaces. This procedure reduces plaque accumulation and facilitates oral hygiene for the patient. Two studies have shown that the combination of resective surgery and implantoplasty results in clinical and radiological improvements over a period of 3 years.^{37,38}

Because resective surgery results in a significant apical displacement of the gingiva and exposure of the endosteal part of the implant, its application might be restricted to the non-aesthetic zone.⁹ Furthermore, it should be remembered that any manipulation of implants could void a manufacturer's guarantee and might only be considered as a last alternative to total implant loss.

5b Regenerative approach

Similar to systematic periodontal therapy, regenerative peri-implantitis treatment should not be considered until initial therapy has reduced signs of acute inflammation.⁹ The two major goals of regenerative therapy are the regeneration of the peri-implant

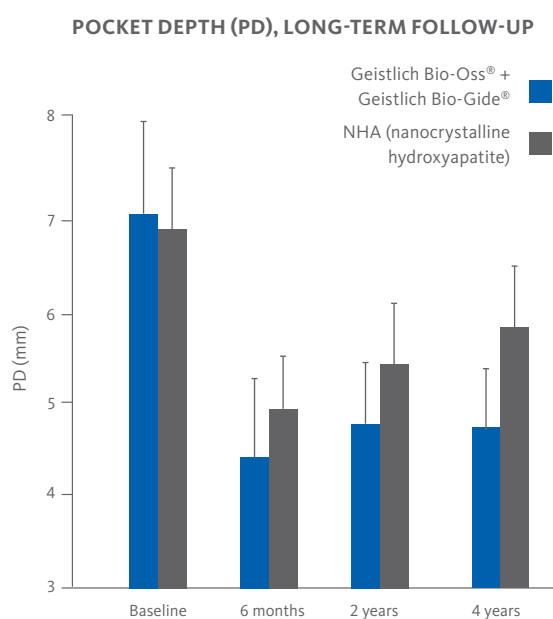


Fig. 7: Surgical regenerative treatment with Geistlich Bio-Oss® and Geistlich Bio-Gide® resulted in higher PD reduction and CAL gains than NHA over a period of 4 years.⁵³

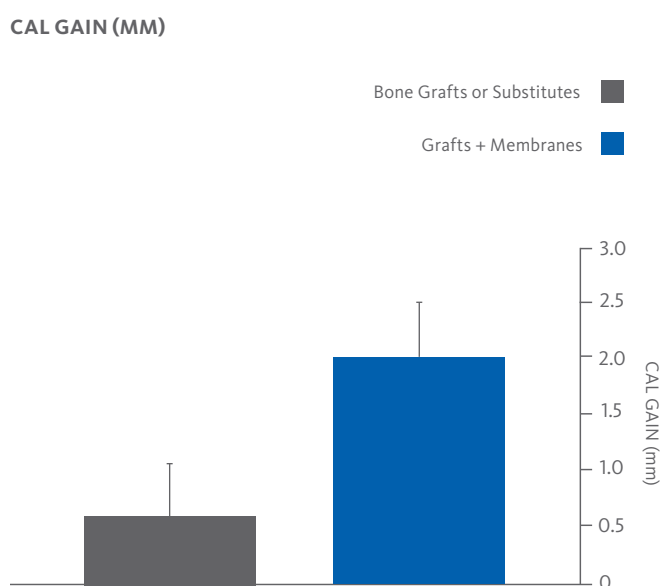


Fig. 8: A recent review indicates that a regenerative approach may be more effective with membranes.⁴⁶ Scientific Evidence on Peri-Implantitis is still limited. 21 Studies (8 RCTs) have been reviewed.



Prof. Mombelli

“At times you find flora on an implant where staphylococci pre- dominate which is untypical with natural teeth. Today we generally use a combination of amoxicillin and metronidazole. And only metronidazole in case of intolerance, but it is not effective against all incriminated microbes.”

bone and the re-osseointegration of the implant. Pre-clinical studies have shown that re-osseointegration of the implant surface is possible following a regenerative approach, but true (histologic) re-osseointegration is yet to be proven in humans.³⁹ Nevertheless, according to systematic literature review, defect fill of peri-implantitis defects following surgical treatment modalities with concomitant placement of bone substitutes is possible.⁴⁰ When defect fill of peri-implantitis defects is required, use of a native bone mineral with or without a collagen membrane has resulted in marked clinical improvements long-term (Fig. 7).⁴¹⁻⁴⁴ Furthermore, Geistlich Bio-Oss® has been found to provide more stable radiographic bone fill than autogenous bone,⁴⁵ and a recent review indicates that using membranes may be more effective (Fig. 8).⁴⁶ However, treatment outcome is greatly influenced by the patient’s systemic health, defect characteristics, implant surfaces and biomaterials used.⁴⁶ Some clinicians combine regenerative and resective approaches. Matarasso and coworkers have shown that a combined regenerative and resective approach yielded positive outcomes in terms of probing depth reduction and radiographic defect fill after 12 months.³⁶ Apical positioning of gingival can be offset by simultaneous soft tissue augmentation with a connective tissue graft⁵⁰ or a porcine collagen matrix – Geistlich Mucograft®⁵¹ – to provide an esthetic outcome in the anterior zone.

Contained intrabony defects, where there are residual bony walls to support grafting, are more suited to a regenerative approach than non-contained defects.⁴⁷

6 Supportive Phase – Maintenance Therapy

The final treatment phase involves an individualized maintenance and care program. Clinical monitoring is recommended on a regular basis and can be supplemented by appropriate radiographic evaluation, as required. Supportive maintenance therapy, including reinforcement of effective oral hygiene and professional bio-film removal, should be provided regularly - usually every 3 to 6 months - as determined by oral health and risk profile. Most relevant considerations include smoking habits, periodontal status, diabetes and oral hygiene history.³⁰

7 Explantation

The clinician can consider implant removal as a treatment option during all stages of peri-implantitis therapy.³⁰ The decision to remove an implant should be based on either absolute or relative symptoms (Fig. 9).⁹

ABSOLUTE SYMPTOMS	RELATIVE SYMPTOMS
Clinical implant mobility due to advanced resorption of the supporting alveolar bone.	<ul style="list-style-type: none"> > Bone loss greater than two-thirds of the implant length > Hollow-cylinder implants > Therapy-resistant peri-implant infections > Implants in medically compromised patients (e.g., tumors, bisphosphonate-associated osteonecrosis of the jaw, etc.).

Fig. 9: Absolute and relative Symptoms whether or not to remove an implant.

Once an explantation decision has been made, several additional factors, such as the implant geometry, diameter, length and the remaining amount of osseointegration, should be considered. Depending on the geometric form and the remaining amount of osseointegration, implants may be unscrewed. In other cases, specific explantation tools must be employed. Care should be taken to preserve residual alveolar bone.⁹

Explantation can be accompanied by bone augmentation to prepare the alveolar ridge for the placement of a new implant.⁹

Regenerative peri-implantitis treatment

Patient's oral health

	AT PERI-IMPLANTITIS DIAGNOSIS	AFTER SURGICAL THERAPY
General periodontal / dental health		
Dental / Oral health	Good	Good
Periodontal health	Healthy	Healthy
Peri-implant health		
Bleeding on Probing at implant (BOP)	Yes	No
Suppuration	Yes	No
Gingival index	3	0
Plaque index	1	0
PD	9 mm	4 mm

RISK FACTORS

Excess luting cement submucosally.

IMPLANT

Site 21; Straumann soft tissue level, diameter: 4.1mm, length: 10 mm, Standard Plus collar 1.8 mm.

MEDICATION

Amoxicillin 500 mg and Metronidazole 400 mg three times a day for 7 days.

OTHERS

Post-operative care included chlorhexidine mouth rinsing (0.2%) twice daily for 1 minute for a period of 4 weeks. 6-monthly maintenance care.

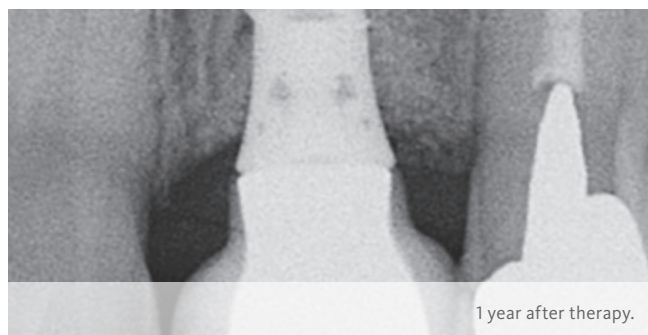
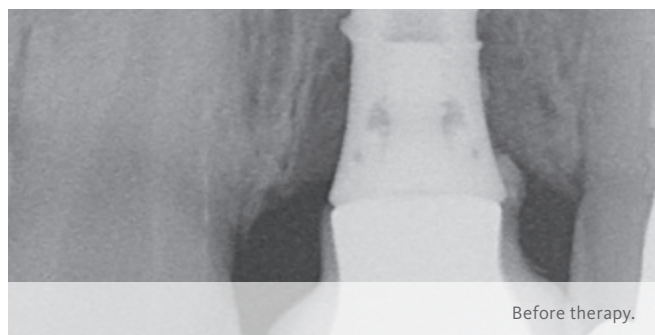
Quintessence

OBJECTIVES

1. Maintain the implant in function. 2. Resolve the peri-implant infection. 3. Regenerate the peri-implant intraosseous defect. 4. Prevent the recurrence of peri-implant infection, surgical access was planned in order to remove the excess luting cement which was clearly visible on the radiograph.

CONCLUSION

3 months following regenerative treatment the infection was resolved. The draining sinus on the mid-facial peri-implant mucosa seen prior to treatment had resolved. At 12 months clinical examination showed a reduction in peri-implant probing depths with resolution of the peri-implant infection.

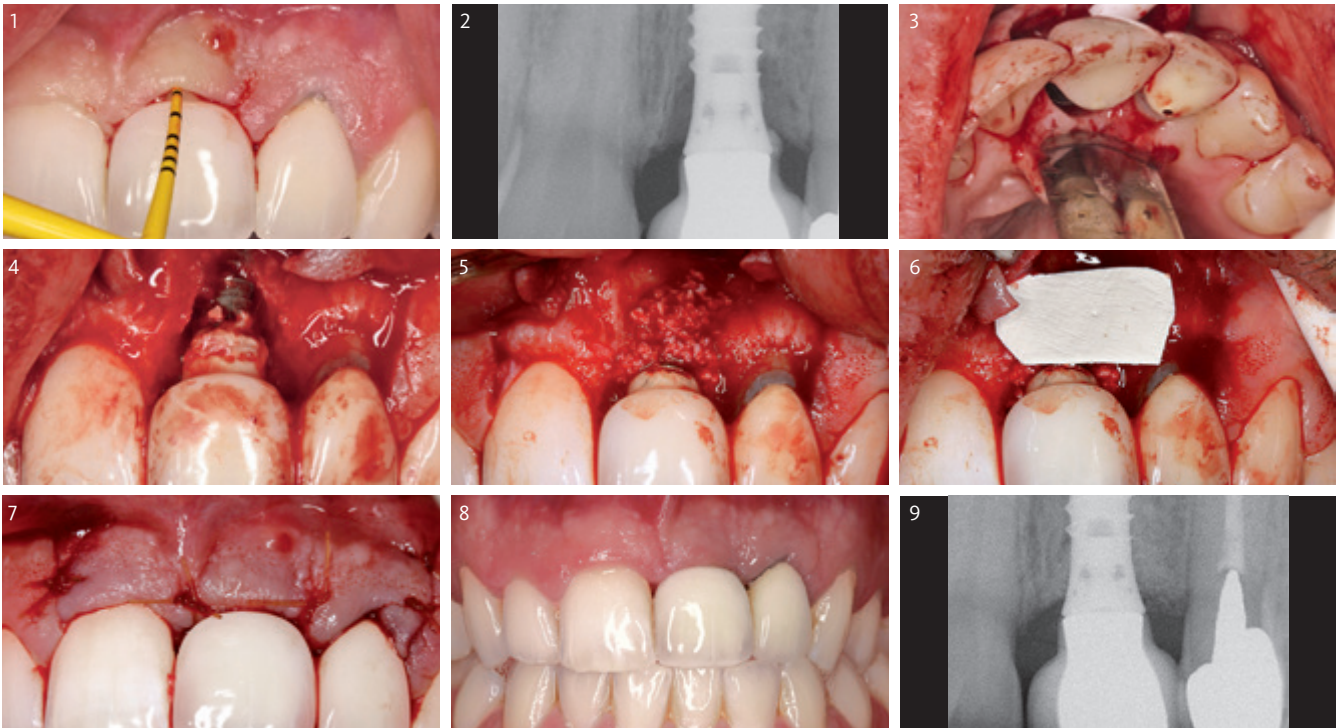




Prof. Lisa J.A. Heitz-Mayfield
Perth (Australia)

MATERIAL SELECTION

Geistlich Bio-Oss® granules (size: 0.25–1 mm)
Geistlich Bio-Gide® (size: 13 mm × 25 mm)



- 1 Clinical situation at initial examination. Deep peri-implant probing depth of 9 mm with bleeding on probing. A draining sinus is observed on the facial peri-implant mucosa. A cemented restoration had been placed at this Straumann soft tissue level implant approximately 4 years prior to the diagnosis of peri-implantitis when the patient was referred for treatment.
- 2 Radiographic view of the marginal bone levels at the implant before treatment. Mesial and distal bone loss is observed extending to the second thread of the implant. Note the radio-opaque material (excess luting cement) on the distal surface of the implant. Also note the calculus on the mesial surface of the tooth 11.
- 3 Palatal view of the intrabony defect. Note the palatal wall is intact, making this defect suitable for regeneration.
- 4 Intraoperative view of the implant and bony defect after flap elevation and before removal of the excess luting cement on the surface of the implant and crown.
- 5 After removal of the inflammatory granulation tissue and decontamination of the implant surface the intrabony portion of the defect is filled with Geistlich Bio-Oss® granules. Note the contour and marginal fit of the crown is not ideal, however the patient did not want to have the crown removed.
- 6 The augmented site is covered with the native collagen membrane Geistlich Bio-Gide®.
- 7 Postoperative view after suturing. The mucoperiosteal flap is closed to cover the membrane and sutures are placed.
- 8 Clinical situation 4 months after regenerative surgical treatment at the implant.
- 9 Follow-up radiograph 12 months post-operatively shows stable bone levels with the defect completely filled.

Aesthetic and functional treatment of peri-implantitis

Patient's oral health

	AT PERI-IMPLANTITIS DIAGNOSIS	AFTER SURGICAL THERAPY
General periodontal / dental health		
Dental / Oral health	Medium	Good
Periodontal health	Periodontitis	Healthy
Peri-implant health		
Bleeding on Probing at implant (BOP)	Yes	No
Suppuration	Yes	No
Gingival index	2	0
Plaque index	3	0
PD	7 mm	3.5 mm

RISK FACTORS

No general risk factors. The implant placed too close to the labial plate. It should have been placed by means of a GBR procedure or with a less narrow implant diameter.

IMPLANT

Brånemark implant external hex type. Implant placement 3 years before peri-implantitis diagnosis.

NON-SURGICAL THERAPY

Non-surgical therapy was performed with scaling and routine cleaning. Patient took amoxicillin 250 mg 3 times a day for 3 days after cleaning.

MEDICATION DURING SURGICAL PHASE

Amoxicillin 250 mg and Tylenol 25 mg 3 times a day for 3 days. Mouth gargle with Chlorhexidine 5 times a day for one week.

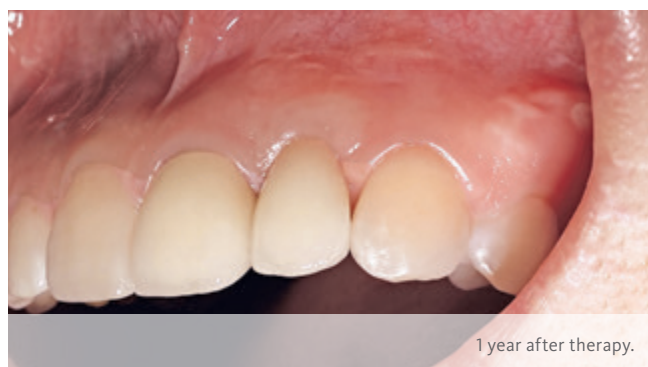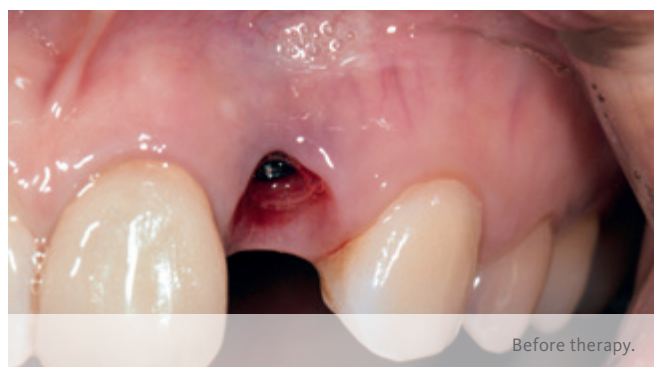Quintessence

OBJECTIVES

- > Aesthetic improvement because of patient complaint about implant shimmering at peri-implantitis site.
- > Regenerate horizontal bone defect for maintaining the implant.

CONCLUSION

- > Improvements in aesthetics with sufficient keratinized soft tissue.
- > Maintenance of implant with stable bony integration.

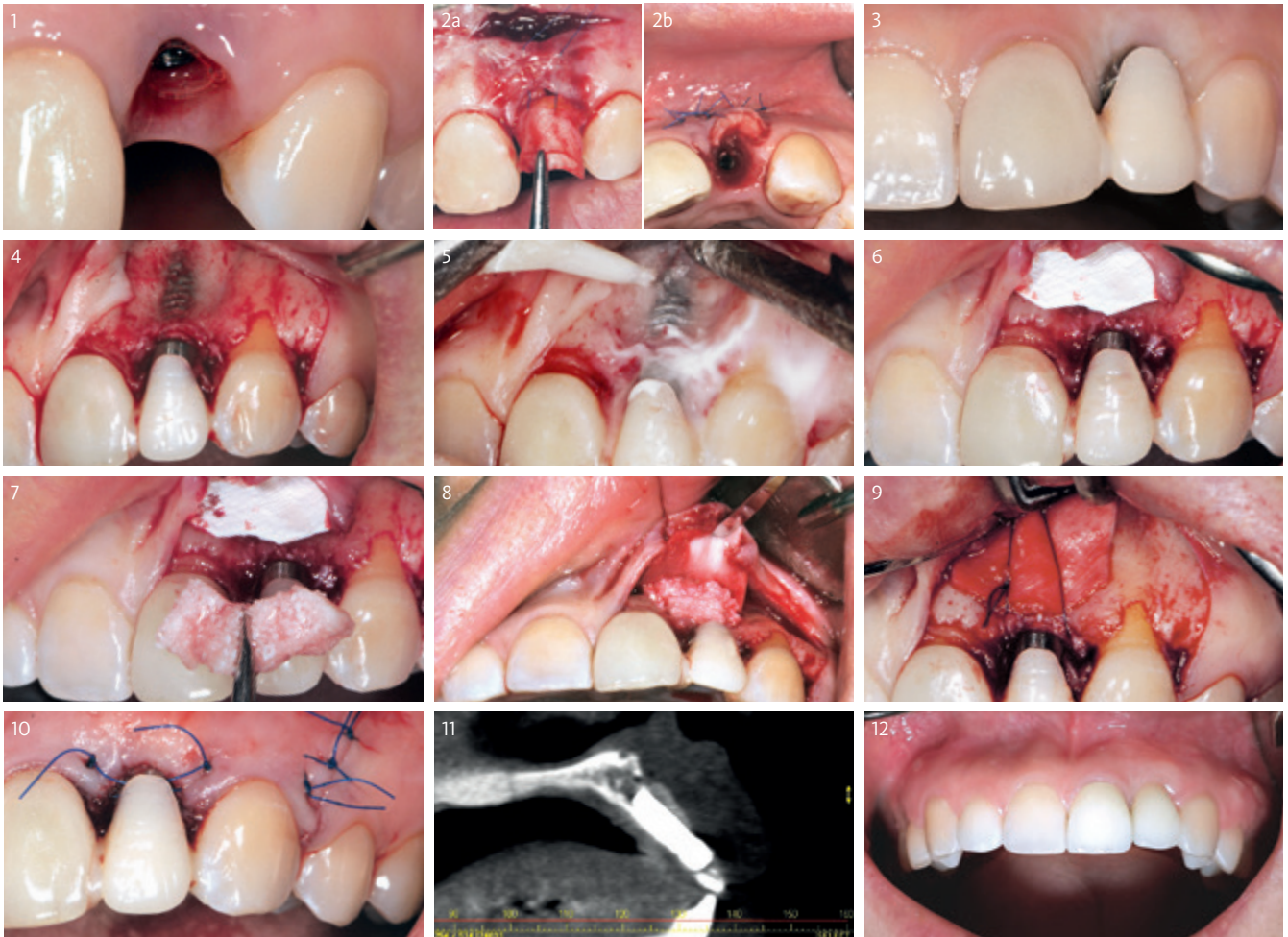




Dr. Dalho Lee
Seoul (South Korea)

MATERIAL SELECTION

Geistlich Bio-Oss® Collagen 100 mg
Geistlich Bio-Gide® 13 × 25 mm
Connective tissue graft



- 1 Clinical situation pre-op indicating the loss of bone and soft-tissue.
- 2 Three months before bone regeneration treatment a soft-tissue augmentation with a connective tissue graft was performed.
- 3 On the day of the second surgery, the peri-implantitis site shows a comfortable soft-tissue situation.
- 4 Intraoperative situation showing the defect. Bone decortication is performed in order to support bone regeneration.
- 5 For decontamination, the implant surface is blasted with beta calciumphosphate and rinsed with saline.
- 6 Geistlich Bio-Gide® is trimmed to the defect size and placed over the defect.
- 7 Geistlich Bio-Oss® Collagen is soaked in saline and shaped to cover the defect.
- 8 The Geistlich Bio-Oss® Collagen is adapted to the defect. It is covered completely by Geistlich Bio-Gide®.
- 9 Geistlich Bio-Gide® is sutured in order to give more stability to the augmented area.
- 10 Clinical view after suturing.
- 11 Post-op CT showing the augmented area on the implant surface.
- 12 Clinical situation 4 months after surgery showing a stable situation.

Peri-implantitis therapy in the posterior mandible

Patient's oral health

	AT PERI-IMPLANTITIS DIAGNOSIS	AFTER SURGICAL THERAPY
General periodontal / dental health		
Dental / Oral health	Medium	Good
Periodontal health	Chronic periodontitis	Chronic periodontitis
Peri-implant health		
Bleeding on Probing at implant (BOP)	Yes	No
Suppuration	Yes	No
Gingival index	2	1
Plaque index	1	0
PD	Max. PD 7 mm	Max. PD 3 mm

RISK FACTORS

Tobacco smoking (5 cigarettes per day).

NON-SURGICAL THERAPY

The first step of the non-surgical therapy includes mechanical debridement with curettes. After rinsing the site, it is further cleaned with ultrasonics and air flow powder (glycine based). As a last step antiseptics are applied: Chlorhexamed (1%) 3 times for 10 minutes.

IMPLANT

Nobel Biocare Replace Straight Groovy. Implant placement 5 years before peri-implantitis diagnosis.

MEDICATION DURING SURGICAL PHASE

Isocillin 1,2 Mega 3 times a day for 7 days.

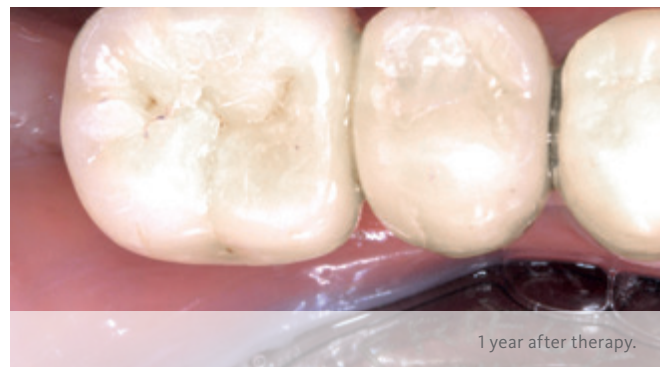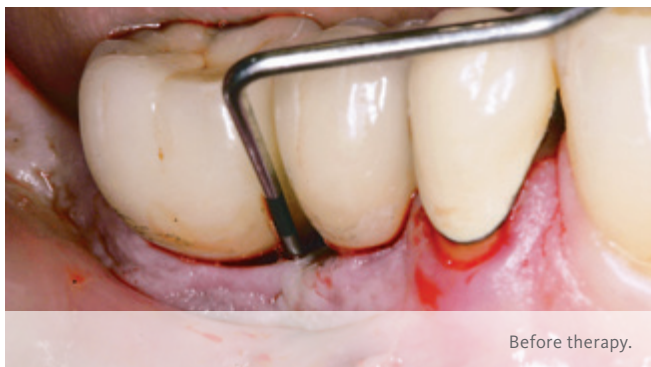Quintessence

OBJECTIVES

- > Functional maintenance of implant in non-aesthetic region.
- > Regenerate circumferential bone defect at implant in position 47.

CONCLUSION

- > Improvements in the patient's oral health were achieved.
- > Implant is integrated in a stable manner one year after peri-implantitis therapy.

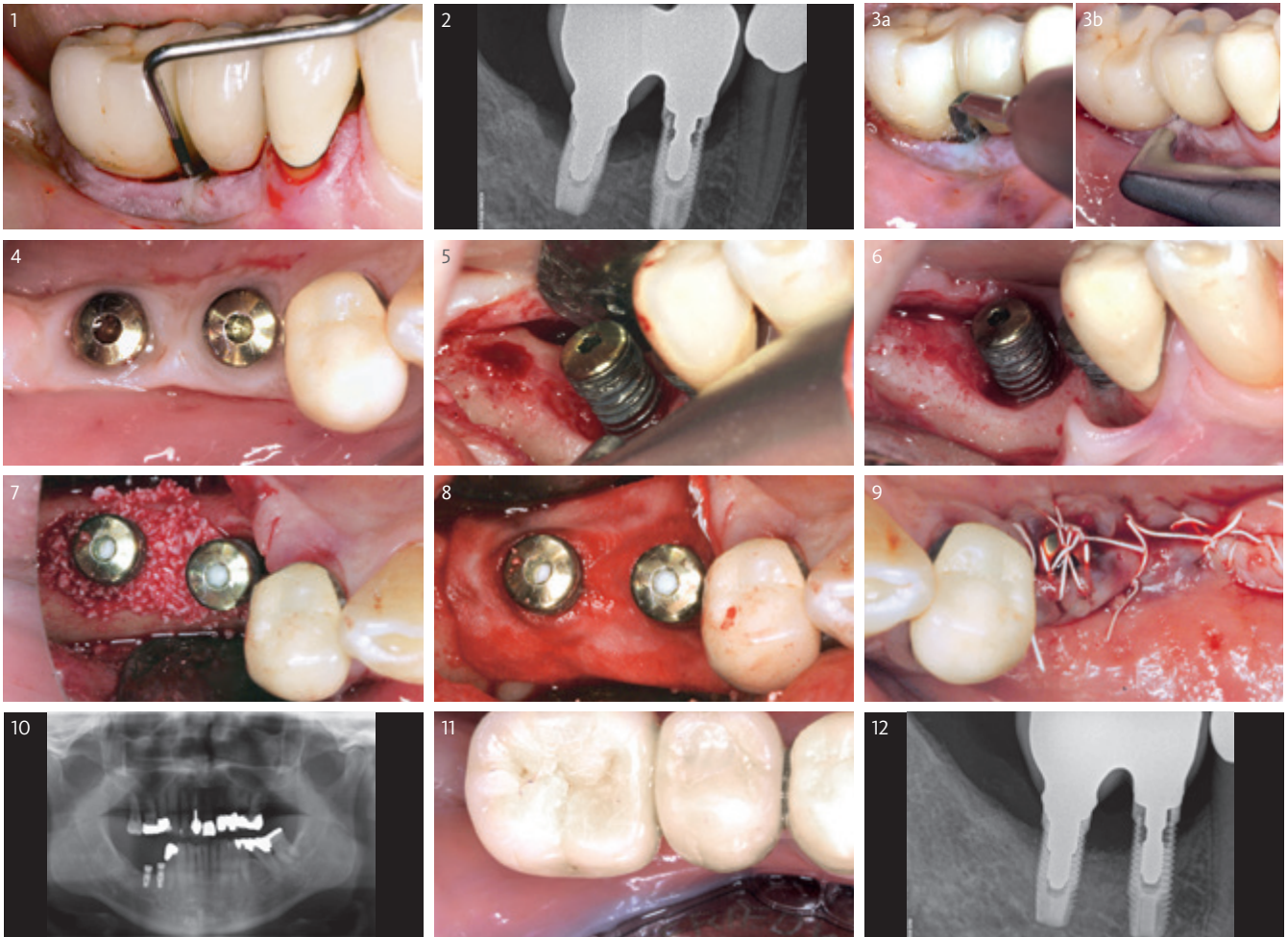




PD Dr. J.M. Stein / Dr. C. Hammächer
Aachen (Germany)

MATERIAL SELECTION

Geistlich Bio-Oss® small granules (0.25–1 mm)
Geistlich Bio-Gide® 25 × 25 mm



- 1 Situation before non-surgical therapy with periodontal probing.
- 2 Radiographic view before non-surgical therapy.
- 3 Non-surgical therapy – Treatment with ultrasonic device (a) and glycine-based air flow powder (b).
- 4 Situation 3 months after post non-surgical therapy following removal of implant crowns and insertion of cover screws.
- 5 Surgical therapy: Intraoperative implant decontamination with powder air abrasion.
- 6 Intraoperative view of the decontaminated peri-implant defect.
- 7 After decontamination, the defect is filled with Geistlich Bio-Oss® granules.
- 8 Coverage with Geistlich Bio-Gide® to stabilize the augmented area.
- 9 Postoperative clinical view after suturing.
- 10 Follow-up picture x-ray after 6 months – panoramic view.
- 11 Follow-up clinical picture after 6 months – Re-establishment of the implant supported crowns.
- 12 Follow-up picture x-ray after 12 months.

Maintenance of implant in the mandible

Patient's oral health

	AT PERI-IMPLANTITIS DIAGNOSIS	AFTER SURGICAL THERAPY
General periodontal / dental health		
Dental / Oral health	Medium	Healthy
Periodontal health	Healthy	Healthy
Peri-implant health		
Bleeding on Probing at implant (BOP)	Yes	No
Suppuration	No	No
Gingival index	1	0
Plaque index	2	0
PD	6–8 mm	3–4 mm

RISK FACTORS

Diabetes patient (Hb1AC value: 7.2%) and insufficient keratinized tissue around the implant.

IMPLANT

Branemark type Nobel Biocare implant, placed 3 months before peri-implantitis diagnosis.

NON-SURGICAL THERAPY

No non-surgical therapy because implant was only placed 3 months before peri-implantitis diagnosis.

MEDICATION DURING SURGICAL PHASE

Amoxicillin 500 mg 3 times a day for 7 days. Localized use of tetracycline 2min scrub for detoxification.

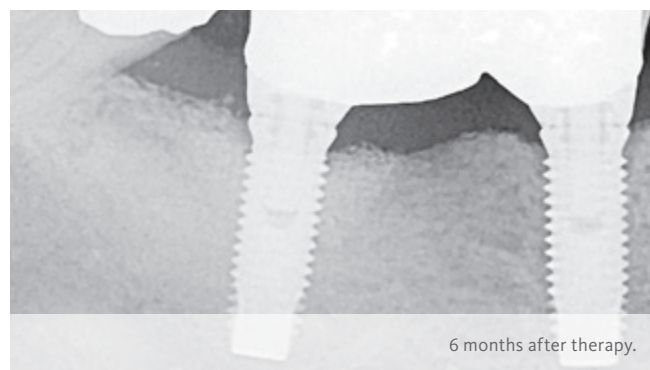

Quintessence

OBJECTIVES

- > Maintenance of implant at site 31.
- > Regenerate circumferential bone and gain keratinized tissue.

CONCLUSION

- > Soft-tissue situation is improved.
- > 6 months after regenerative surgery, implant is integrated in a stable manner into the surrounding bone.

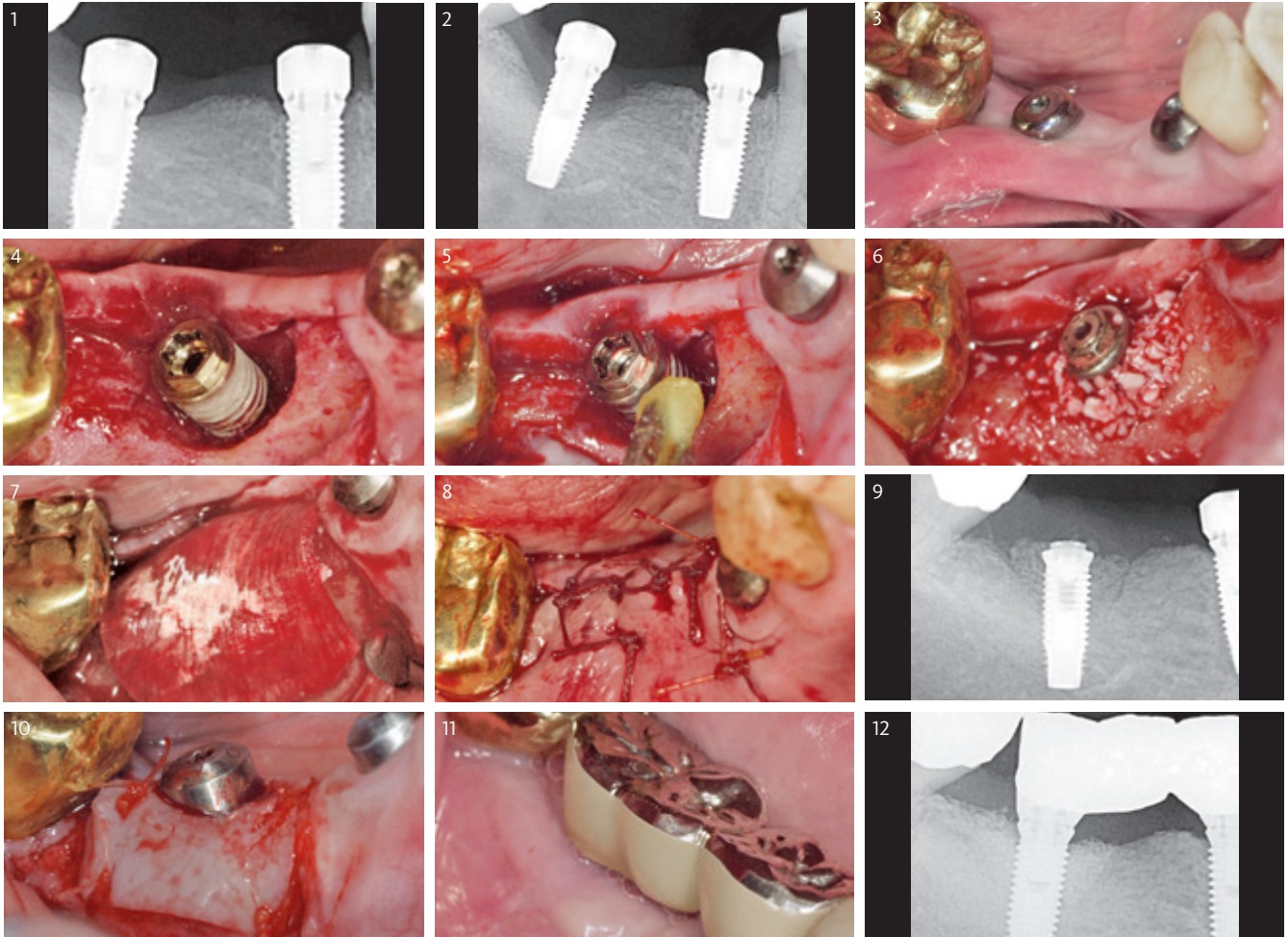




Dr. Brad McAllister
Portland (United States of America)

MATERIAL SELECTION

Geistlich Bio-Oss® small granules (0.25–1 mm)
Geistlich Bio-Gide® 25 × 25 mm
Free Gingival Graft (FGG)



- 1 Radiograph after implant insertion showing stable bony situation.
- 2 The radiographic view 3 months post-op shows the progressive bone loss compared to the initial situation due to peri-implantitis.
- 3 The clinical situation of the peri-implantitis site pre-op. The lack of keratinized soft tissue is noteworthy.
- 4 Intraoperative view showing the crater-like defect around the implant.
- 5 The implant surface is cleaned with tetracycline slurry which was placed on cotton pellets.
- 6 The bony defect is filled with Geistlich Bio-Oss® granules.
- 7 The whole augmented area is covered with a Geistlich Bio-Gide® membrane.
- 8 Clinical view after closing the defect with tension-free sutures.
- 9 Radiograph taken directly after surgery.
- 10 5 months after regenerative bone augmentation, a Free Gingival Graft (FGG) is used to improve the soft-tissue situation as seen in picture 3.
- 11 Clinical situation with final restoration 6 months after bone augmentation procedure.
- 12 The radiograph after 6 months shows a stable filling of the defect around the implant.

Implant therapy to restore missing posterior dentition

Patient's oral health

	AT PERI-IMPLANTITIS DIAGNOSIS	AFTER SURGICAL THERAPY
General periodontal / dental health		
Dental / Oral health	Good	Good
Periodontal health	Healthy	Healthy
Peri-implant health		
Bleeding on Probing at implant (BOP)	Yes	Yes (only mesial)
Suppuration	Yes	No
Gingival index	2	1
Plaque index	1	2
PD	>10mm b/m/d/l	2 mm b/d/l; 4 mm m

RISK FACTORS

No risk factors.

IMPLANT

Astra Tech 4.5 mm × 13 mm TioBlast Implant placement 10 years before peri-implantitis diagnosis.

NON-SURGICAL THERAPY

Deep irrigation with chlorhexidine and application of topical minocycline gel ×2. Additionally, topical minocycline 2% was administered.

MEDICATION DURING SURGICAL PHASE

Amoxicillin 3 g (prophylactic), Tetracycline 1g in 20 mL sterile saline local, Amoxicillin 250 mg TDS 1 week post-op. Co-codamol 500/8 mg 4–6 hrly, 2 days, Dexamethasone reducing dose 8 mg, 6 mg, 4 mg, 2 mg over 4 days. Chlorhexidine mouthwash b.d. (twice daily) 1 week.

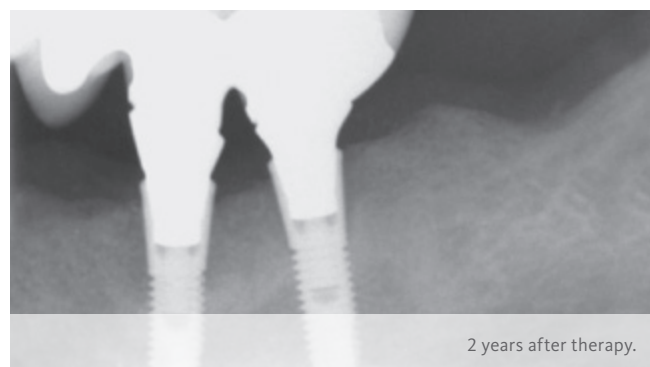
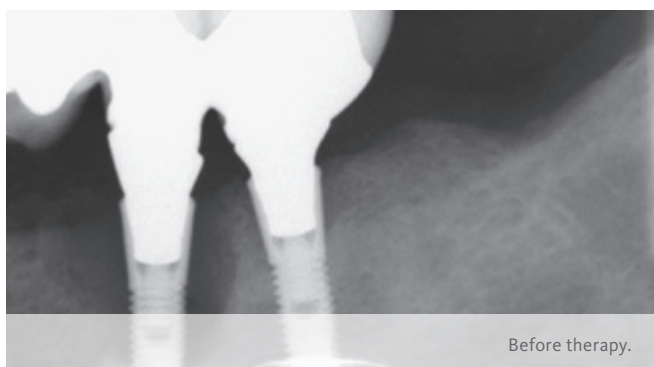
Quintessence

OBJECTIVES

- > Restore 4 quadrants of missing posterior dentition.
- > Regenerate bone defect with 3 bony walls remaining.

CONCLUSION

- > Posterior dentition could be restored.
- > Situation is stable up to two years.

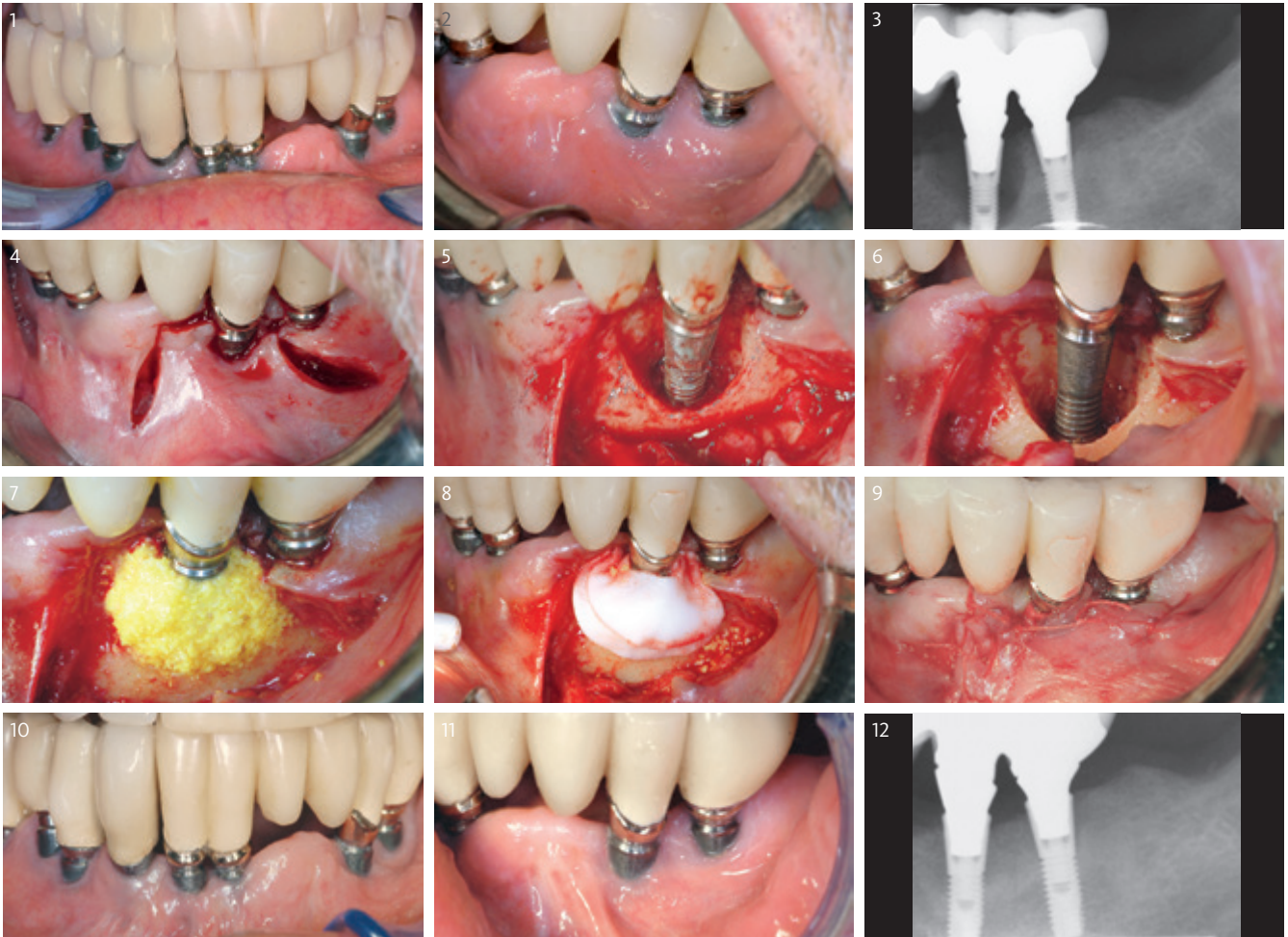




Michael R. Norton
London (United Kingdom)

MATERIAL SELECTION

Geistlich Bio-Oss® small granules (0.25–1 mm)
Geistlich Bio-Gide® 25 × 25 mm



- 1 Whole mouth area 10 years after implants have been inserted.
- 2 Pre-op clinical view of the peri-implantitis site at tooth 35.
- 3 In the radiograph a deep crater-like defect is observable around the implant.
- 4 A flap is prepared in order to get access to the defected implant surface.
- 5 Intraoperative situation showing the extended bone loss around the implant.
- 6 The implant surface is cleaned and decontaminated with Chlorhexidine 0.2%. Exposure for 3–5 minutes followed by Tetracycline wash 1g in 20 mL of sterile saline.
- 7 The peri-implant bone defect is filled with Geistlich Bio-Oss® granules (rehydrated in a tetracycline solution).
- 8 A trimmed Geistlich Bio-Gide® is applied as a double layer in order to stabilize the defect.
- 9 Postoperative clinical view after suturing.
- 10 Whole mouth area two years after peri-implantitis treatment.
- 11 Clinical view of the peri-implantitis site. The implant could be maintained as a result of the peri-implantitis treatment.
- 12 Follow-up radiograph after two years shows the integration of the implant into newly formed bone.

Aesthetic and functional peri-implantitis therapy in the maxilla

Patient's oral health

	AT PERI-IMPLANTITIS DIAGNOSIS	AFTER SURGICAL THERAPY
General periodontal / dental health		
Dental / Oral health	Good	Good
Periodontal health	Healthy	Healthy
Peri-implant health		
Bleeding on Probing at implant (BOP)	Yes	No
Suppuration	Yes	No
Gingival index	3	1
Plaque index	1	0
PD	4/9/3/10	All < 3 mm

RISK FACTORS

No risk factors. Patient suffered heavy pain after crown insertion. Pain receded after a couple of weeks.

IMPLANT

Ankylos; 3.5 mm diameter, 11 mm length; implant placement 4 years before peri-implantitis diagnosis.

NON-SURGICAL THERAPY

Removal of the crown, rinsing with Chlorhexidine-Gel and placement of a cover screw.

MEDICATION DURING SURGICAL PHASE

Amoxicillin 750 mg 3 times a day for one week, Chlorhexidine gel rinsing 3 times a day 0.2%. Pain killer mefenamic acid.

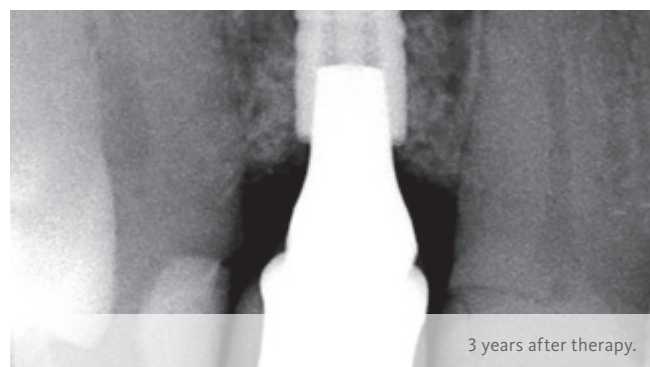
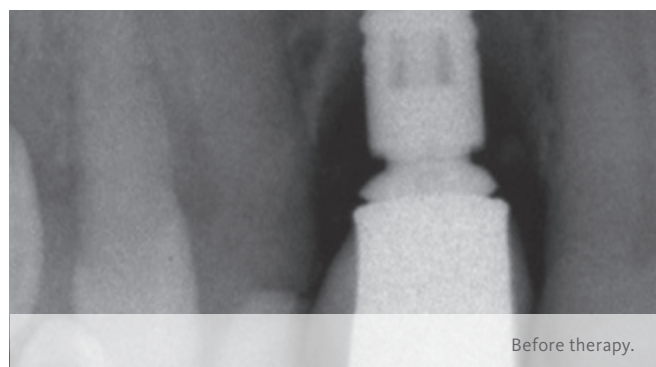
Quintessence

OBJECTIVES

- > To restore Peri-implant health, preserve aesthetics and function.
- > To treat the circumferential, mainly vertical infrabony defect in order to rebuild the lost hard tissue and to preserve the soft-tissue volume.

CONCLUSION

- > Pleasing aesthetic soft-tissue situation could be achieved.
- > 3 years after regenerative surgery, the implant still integrated in a stable manner into the regenerated bone.

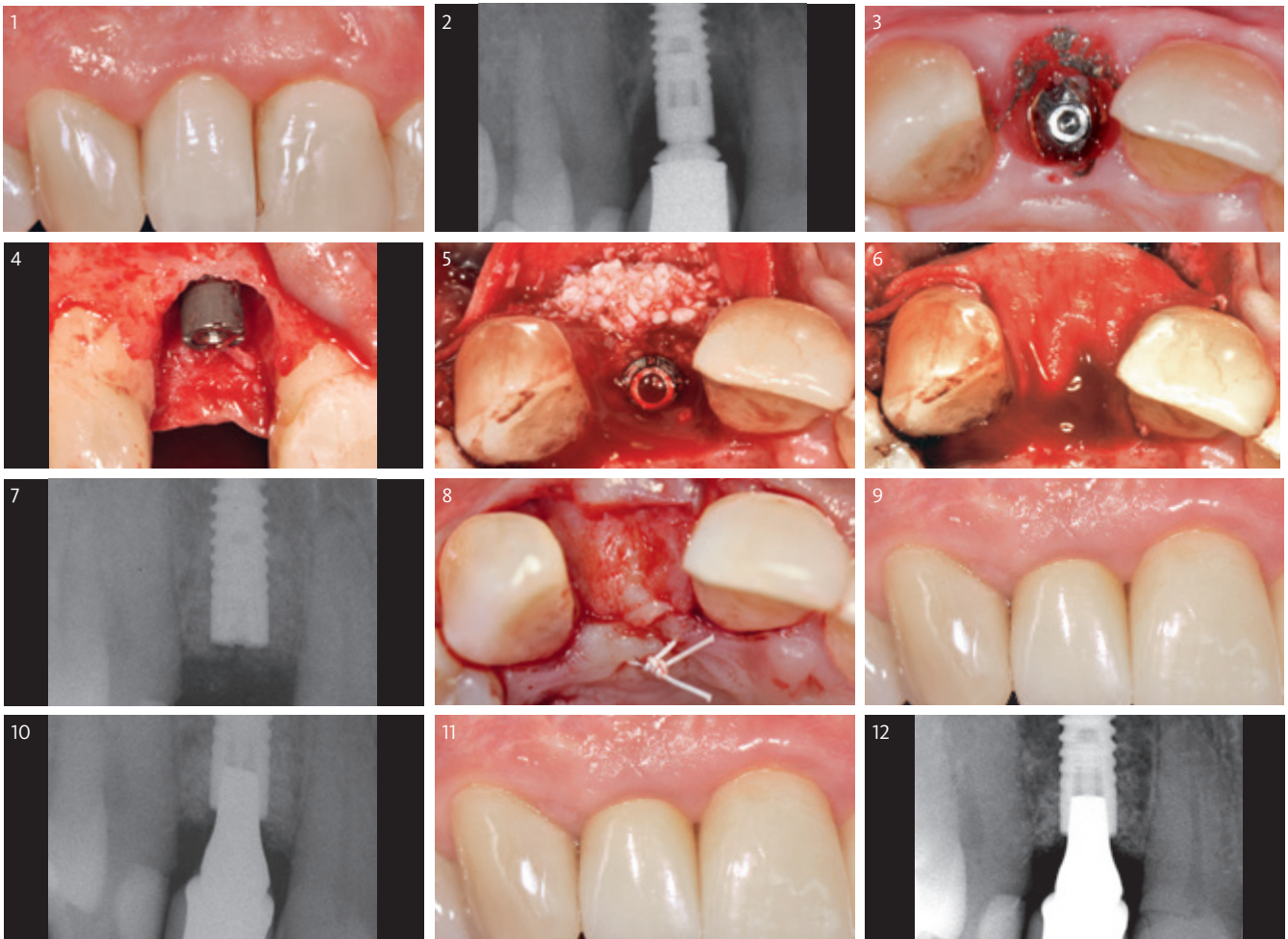




Christian Ramel
Zurich (Switzerland)

MATERIAL SELECTION

Geistlich Bio-Oss® large granules (1–2 mm)
Geistlich Bio-Gide® 25 × 25 mm
Connective Tissue Graft



- 1 Clinical situation 4 years after implant placement.
- 2 Radiograph shows a peri-implant bone defect. The crown margin is located far too submucosally. A gap is visible in between the abutment and the crown.
- 3 When removing the crown, massive cement excess was visible at the former crown margin. The soft tissue shows accentuated signs of inflammation. The site is rinsed with chlorhexidine for decontamination. A cover screw was applied and left submucosally for healing.
- 4 3 months after crown removal, access flap surgery was performed. A circumferential bone defect is visible.
- 5 Geistlich Bio-Gide® is placed and filled underneath with Geistlich Bio-Oss® covering the whole defect area.
- 6 Geistlich Bio-Gide® completely covers the augmented area and is closed with a tension-free flap.
- 7 Radiograph directly after regenerative surgery.
- 8 After 2 months of healing a connective tissue graft is used to improve the soft-tissue situation.
- 9 6 months after regenerative surgery the final prosthesis is fixed. Clinical situation shows good soft-tissue healing.
- 10 The radiograph at delivery of final crown displays stable bony situation.
- 11 Clinical situation 3 years after regenerative surgery displays a stable aesthetic result.
- 12 A long-term follow-up radiograph after 3 years shows a stable bony situation.

Regeneration of deep peri-implantitis induced bony defect

Patient's oral health

	AT PERI-IMPLANTITIS DIAGNOSIS	AFTER SURGICAL THERAPY
General periodontal / dental health		
Dental / Oral health	Good	Good
Periodontal status	Chronic periodontitis	Treated chronic periodontitis
Peri-implant health		
Bleeding on Probing at implant (BOP)	Yes	No
Suppuration	Yes	No
Gingival index	2	0
Plaque index	0	0
PD (in mm)	9/11/8/11	3/3/2/3

RISK FACTORS

No risk factors.

NON-SURGICAL THERAPY

Scaling & root planing.

IMPLANT

SP Ø4.1 RN 12 mm implant placement 6 years before peri-implantitis diagnosis.

MEDICATION DURING SURGICAL PHASE

Augmentin 1g bid × 6 days.

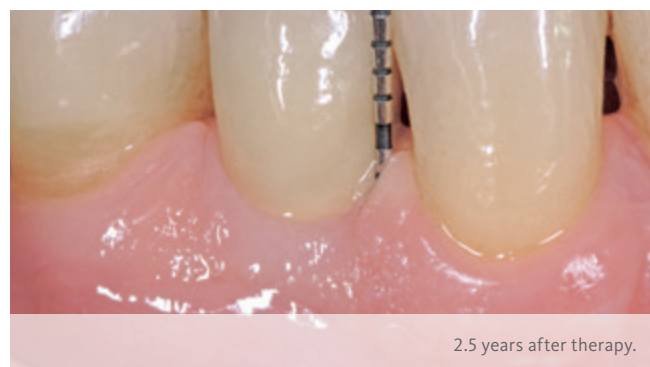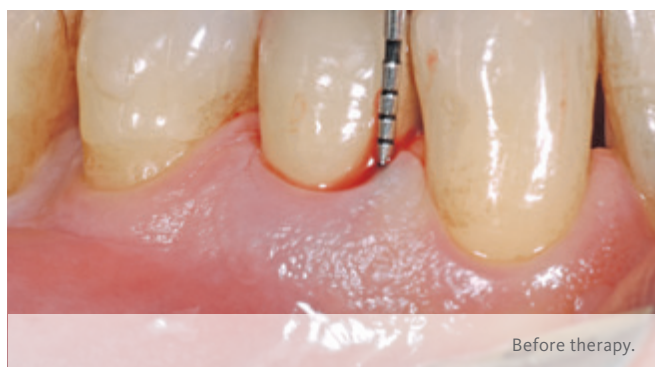Quintessence

OBJECTIVES

- > Functional restoration of implant.
- > Regenerate circumferential bone defect at implant in position 44.

CONCLUSION

- > Deep bone defect could be regenerated.
- > Peri-implant tissues could be restored to health, 8 years after placement.

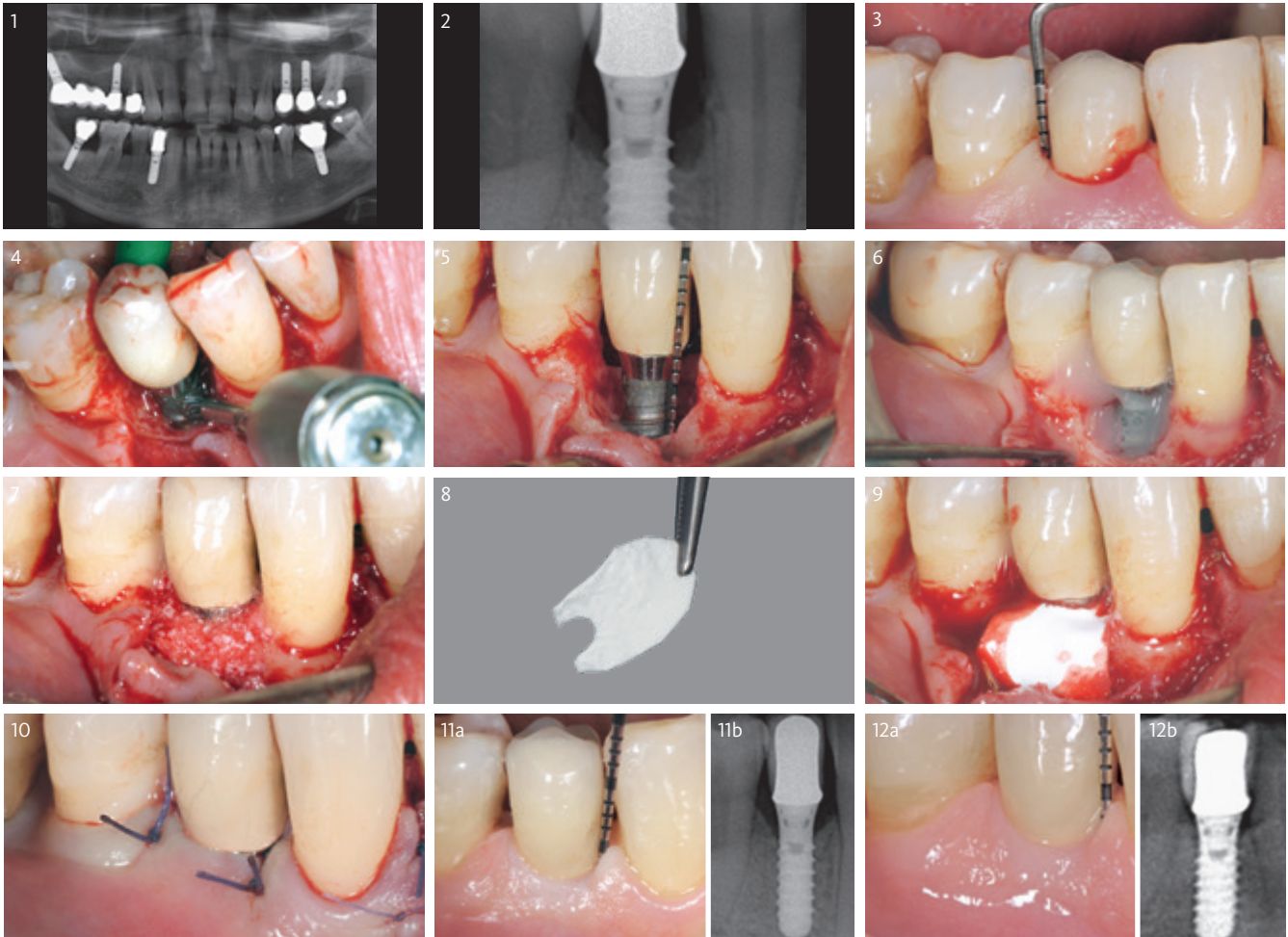




Mario Rocuzzo
Torino (Italy)

MATERIAL SELECTION

Geistlich Bio-Oss® Collagen 100 mg
Geistlich Bio-Gide® 25 × 25 mm



- 1 Orthopantomography 4 years after implant insertion shows stable interproximal bone around implant in 44.
- 2 Two years later (6 years after implant placement) peri-implant bone loss is visible around the implant.
- 3 Deep pocket and bleeding on probing mesial and distal to the implant.
- 4 After raising a full thickness flap the surface of the implant is cleaned with a titanium brush.
- 5 Peri-implant lesion after the removal of granulation tissue and before decontamination of the implant surface.
- 6 EDTA is applied to the implant surface to decontaminate the implant surface.
- 7 Geistlich Bio-Oss® Collagen is applied around the implant in the peri-implantitis defect.
- 8 Geistlich Bio-Gide® is trimmed to cover the the defect area.
- 9 Geistlich Bio-Gide® is positioned to cover Geistlich Bio-Oss® and provide stability to the augmented site.
- 10 Non-submerged 4-0 Vycril suture of the flap.
- 11 Radiograph and clinical situation at 1-year post op. Minimal probing depth mesial and distal to the defect shows the defect elimination of the peri-implantitis site.
- 12 Clinical and radiographical situation 2.5 years post-up shows stable conditions.

Regenerative therapy of peri-implantitis defect in the mandible

Patient's oral health

	AT PERI-IMPLANTITIS DIAGNOSIS	AFTER SURGICAL THERAPY
General periodontal / dental health		
Dental / Oral health	Healthy dentition	Healthy dentition
Periodontal health	No history of treated periodontitis	No history of treated periodontitis
Peri-implant health		
Bleeding on Probing at implant (BOP)	Yes	No
Suppuration	Yes	No
Gingival index	2	0
Plaque index	0	0
PD	7/6/6/7	3/3/2/3

RISK FACTORS

Patient systemically healthy, non-smoker.

IMPLANT

Mesial and distal excess cement.

NON-SURGICAL THERAPY

The cemented crown was not removed. The mesial and distal excess cement was removed during non-surgical peri-implantitis therapy of implant 45.

MEDICATION AFTER SURGICAL PHASE

- > 0.2% Chlorhexidine rinsing.
- > Voltarene Rapid 50 mg.
- > Systemic antibiotics (Amoxicillin).

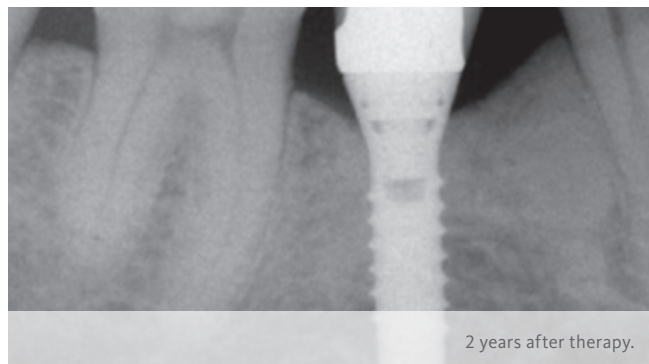
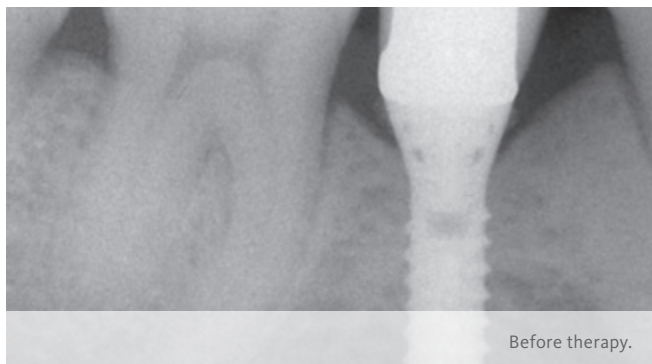
Quintessence

OBJECTIVES

- > Access flap and removal of granulation tissue.
- > Decontamination of exposed implant surface.
- > Regenerative treatment to improve bony situation.

CONCLUSION

- > Peri-implant inflammation is resolved (i.e. absence of bleeding and suppuration).
- > Shallow residual probing pocket depths.
- > Depth of the intraosseous defect is reduced.

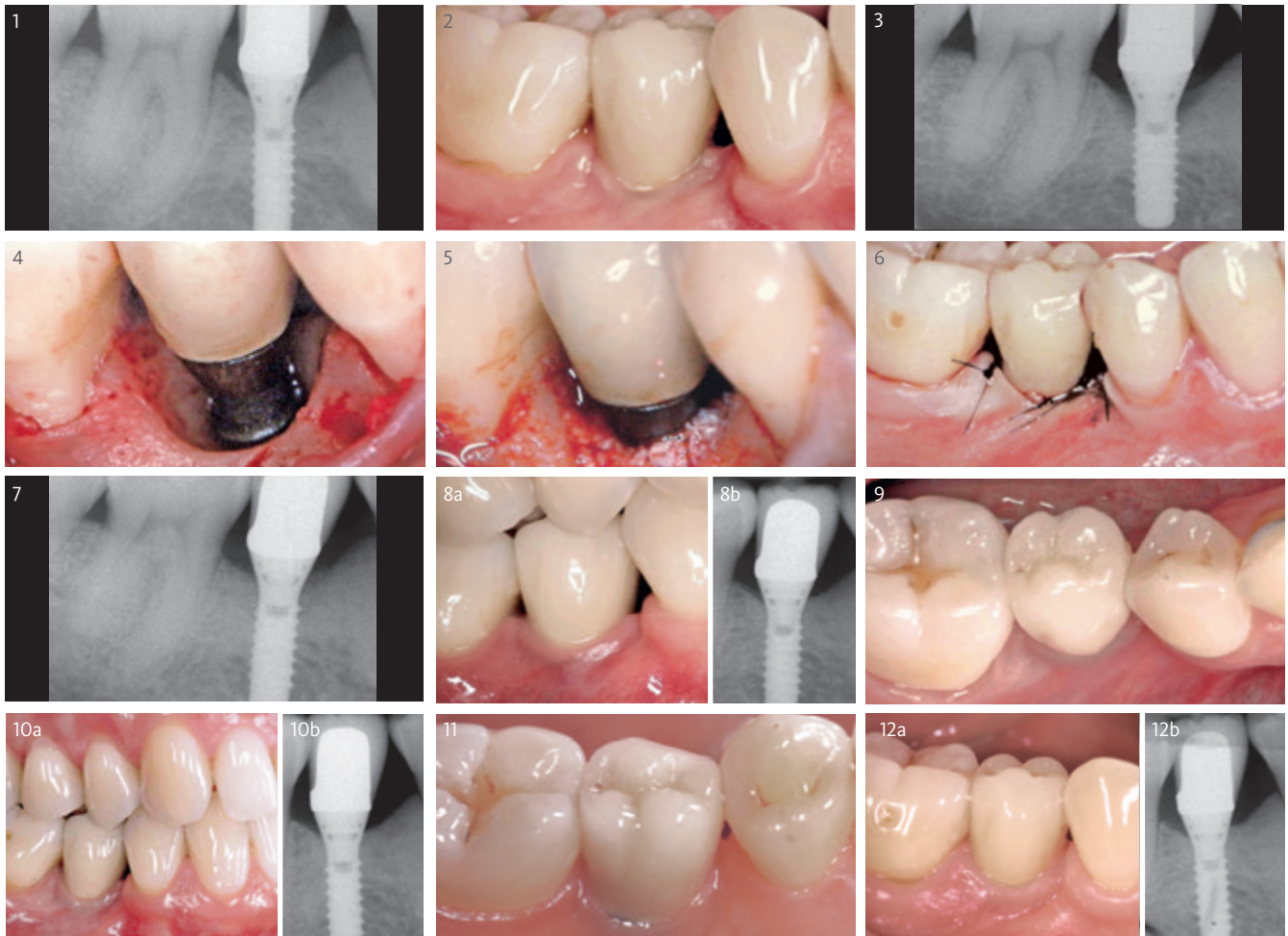



Prof. Giovanni E. Salvi
Bern (Switzerland)

MATERIAL SELECTION

Geistlich Bio-Oss® 0.25–1mm small granules
Geistlich Bio-Gide® 25 × 25 mm



- 1 Radiograph at delivery of restoration displaying excess cement at the mesial and distal aspect of implant 45.
- 2 Three years following delivery of the cemented crown, signs of mucosal inflammation are visible around implant 45. On patient request, the cemented crown was not removed.
- 3 Radiograph showing the crater-like bony defect. Excess cement was previously removed in the nonsurgical phase.
- 4 The crater-like bony defect is visible following mucoperiosteal flap elevation. Following removal of the granulation tissue, decontamination of the implant surface was performed by means of 0.2% chlorhexidine and saline.
- 5 Geistlich Bio-Oss® was applied into the defect around implant 45. A Geistlich Bio-Gide® membrane was adapted over the Geistlich Bio-Oss® granules around the implant neck (not shown).
- 6 Transmucosal healing of implant 45 after regenerative therapy.
- 7 Post-surgical radiograph of the peri-implant defect filled with Geistlich Bio-Oss® granules.
- 8 Clinical buccal image of implant 45 two years after regenerative therapy showing healthy soft tissue conditions. The radiographic image shows hard tissue filled mesially and distally from implant 45.
- 9 Occlusal clinical image 6 years after regenerative therapy.
- 10 Clinical buccal image 6 years after regenerative therapy showing healthy soft tissue conditions. The patient demonstrates excellent oral hygiene. The radiographic image shows hard tissue filled mesially and distally from implant 45.
- 11 Lingual clinical image of implant 45 nine years after regenerative therapy.
- 12 Clinical buccal situation of implant 45 nine years after regenerative therapy. A stable clinical and x-ray situation is in evidence.

Regenerative therapy combined with implant plastic surgery

Patient's oral health

	AT PERI-IMPLANTITIS DIAGNOSIS	AFTER SURGICAL THERAPY
General periodontal / dental health		
Periodontal health	Healthy	Healthy
Peri-implant health		
Bleeding on Probing at implant (BOP)	100 %	0 %
Suppuration	Yes	No
Gingival index	Not assessed	Not assessed
Plaque index	< 1	< 1
PD	> 8 mm	< 5 mm

RISK FACTORS

No systemic risk factors.

MEDICATION DURING SURGICAL PHASE

Peri- and postoperative (5 days) Amoxicillin 1000 mg.

IMPLANT

Straumann Tissue Level implants.

NON-SURGICAL THERAPY

Mechanical debridement and local antiseptic therapy using CHX.

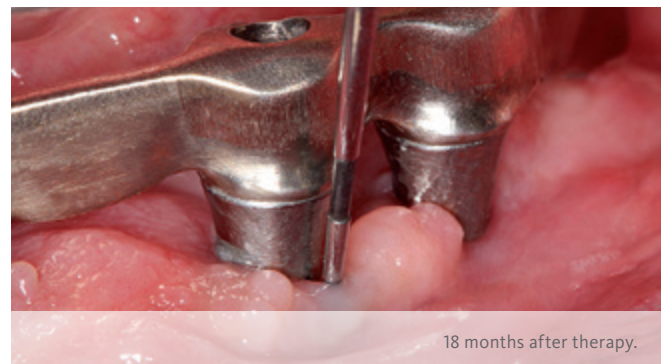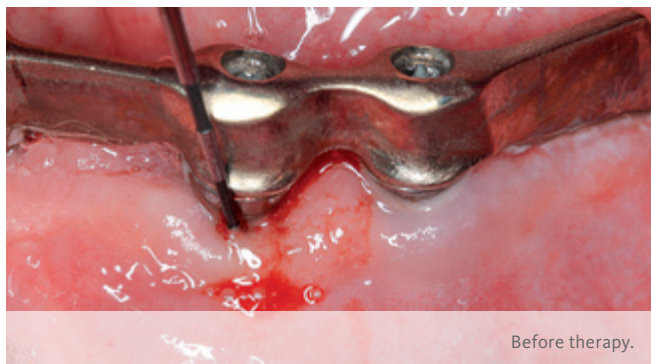
Quintessence

OBJECTIVES

- > Regeneration of bony defect due to peri-implantitis.
- > Restoration of implant in the mandible.

CONCLUSION

- > Stable bone and soft-tissue situation after regenerative surgery.
- > Disease resolution and radiographic defect fill.

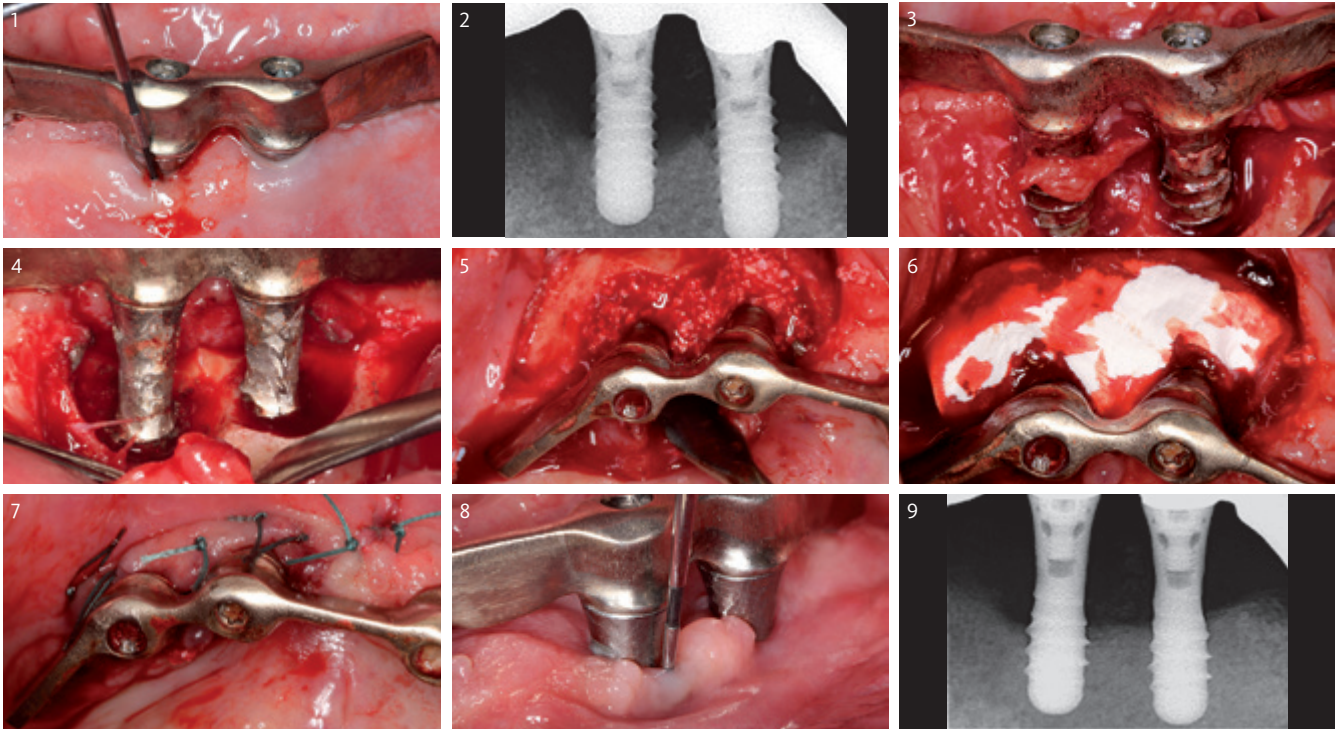




Prof. Frank Schwarz
Düsseldorf (Germany)

MATERIAL SELECTION

Geistlich Bio-Oss® small granules (0.25–1 mm)
Geistlich Bio-Gide® 25 × 25 mm



- 1 Bleeding and suppuration on two implants in Region 033 and 034.
- 2 The radiograph shows combined supra-crestal- and intrabony defects.
- 3 After access flap surgery, the granulation tissue was thoroughly removed from the combined defects using conventional curettes.
- 4 Situation after implantoplasty. Smoothing of the exposed parts of the threads at both supra-crestal and buccal aspects.
- 5 Following decontamination, the intraosseous defect area is filled with Geistlich Bio-Oss®.
- 6 The Geistlich Bio-Gide® collagen membrane cut to size in situ.
- 7 The edges of the wound are adapted tightly around the implants.
- 8 Clinical situation free of inflammation at 18-months.
- 9 Radiograph after 12-months – the structured implant components are covered at the bone level.

Regenerative therapy of peri-implantitis in the posterior region

Patient's oral health

	AT PERI-IMPLANTITIS DIAGNOSIS	AFTER SURGICAL THERAPY
General periodontal / dental health		
Dental / Oral health	Good	Good
Periodontal health	Healthy	Healthy
Peri-implant health		
Bleeding on Probing at implant (BOP)	Yes	No
Suppuration	Yes	No
Gingival index	2	1
Plaque index	0	0
PD	7 mm	2 mm

RISK FACTORS

Low risk.

IMPLANT

Astra Implant 4.0 mm × 11 mm TioBlast Implant placement 10 years before peri-implantitis diagnosis.

NON-SURGICAL THERAPY

- > Betadine was administered.
- > Systemic antibiotics (amoxicillin 1.5 twice a day × 6 days).

MEDICATION DURING SURGICAL PHASE

- > Amoxicillin 2 g (prophylactic).
- > Chlorhexidine 0.12% alcohol-free mouthwash b.d. 1 week.
- > Pain killer Ibuprofen 400 mg on demand.

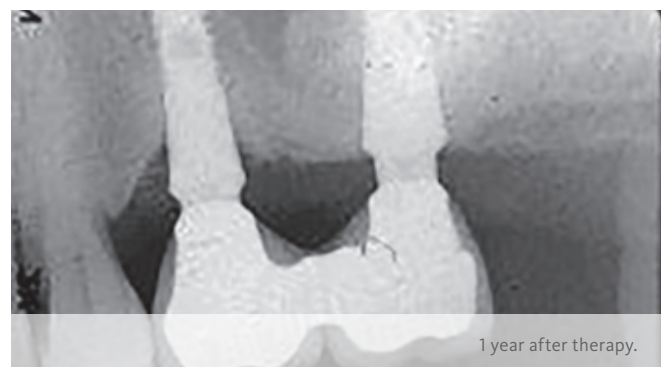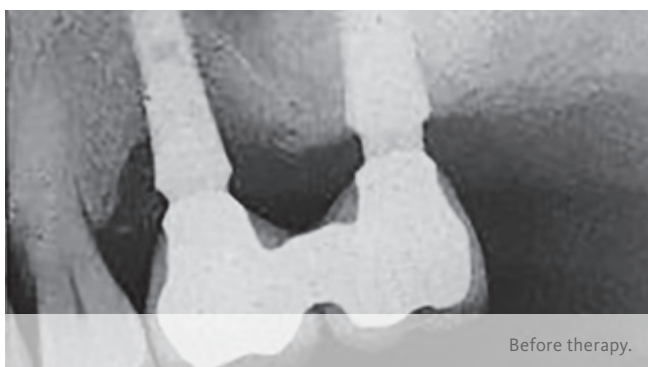Quintessence

OBJECTIVES

- > Maintain the implant.
- > Regenerate bone defect with 3 bony walls remaining.

CONCLUSION

- > Posterior implant and prosthesis could be restored.
- > Situation is stable up to 12 months.

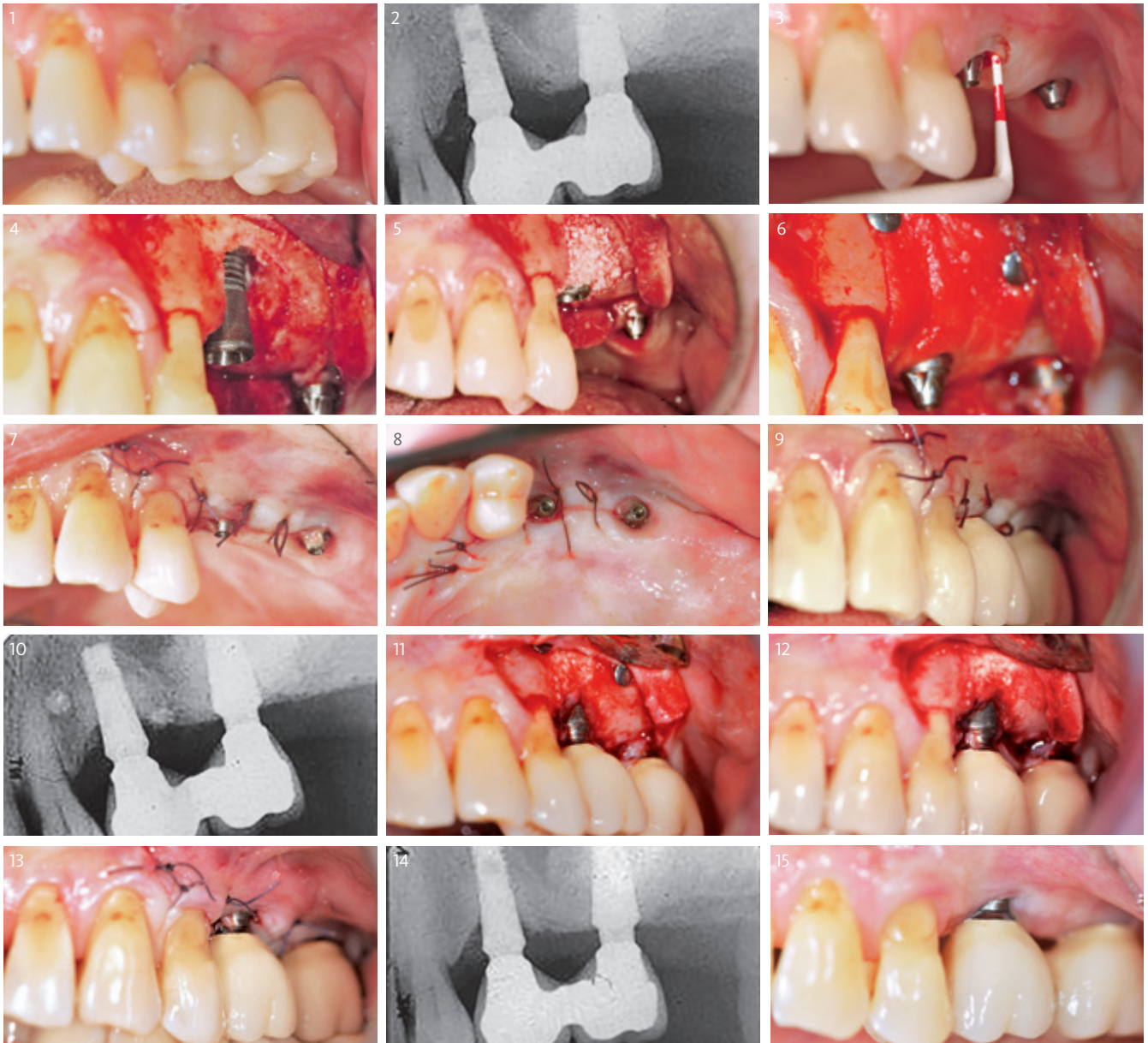



Jean-Louis Giovannoli
Paris (France)

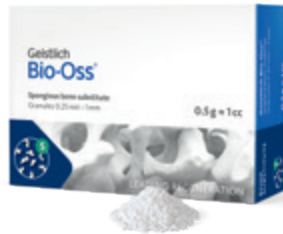MATERIAL SELECTION

Geistlich Bio-Oss® small granules (0.25–1 mm)
Geistlich Bio-Gide® 25 × 25 mm
Titanium micro pins Dentsply Frios®



- 1 Initial clinical view.
- 2 X-ray with a crater like-defect around implant in region 25.
- 3 Pre-op view after bridge removal. The use of a periodontal probe shows a 7mm pocket depth.
- 4 View of the defect after debridement and decontamination of exposed implant surface.
- 5 Filling with Geistlich Bio-Oss® humected by saline.
- 6 A trimmed Geistlich Bio-Gide® is applied to cover the Geistlich Bio-Oss® and is stabilized by 2 titanium micro-pins.
- 7/8 Buccal/Palatal view of the suturing technique.
- 9 Suturing technique with the screw-retained bridge in place.
- 10 Follow-up radiograph after 11 months of healing.
- 11 Defect filled with newly regenerated tissue (at 11 months).
- 12 The 2 titanium micro-pins are removed.
- 13 Buccal view of the suturing technique.
- 14 Follow-up radiograph after 12 months (1 month after re-entry).
- 15 Final clinical view.

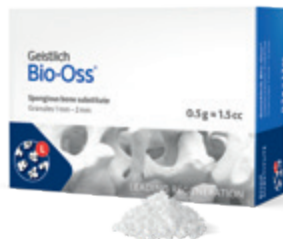Product range



GEISTLICH BIO-OSS®

Small granules (0.25–1 mm) | Quantities: 0.25 g, 0.5 g, 1.0 g*, 2.0 g (1 g ≈ 2.05 cm³)

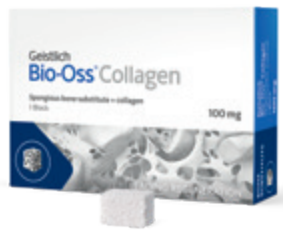The small Geistlich Bio-Oss® particles allow close contact with the surrounding bone wall. They are recommended for smaller 1–2 socket defects and for contouring autogenous block grafts.



GEISTLICH BIO-OSS®

Large granules (1–2 mm) | Quantities: 0.5 g, 1.0 g*, 2.0 g (1 g ≈ 3.13 cm³)

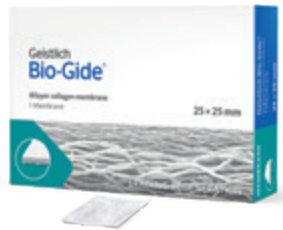

The large Geistlich Bio-Oss® granules have more space between the particles than the small granules. Particularly in large defects, this enables improved regeneration over large distances and provides enough space for the ingrowing bone.



GEISTLICH BIO-OSS® COLLAGEN

Geistlich Bio-Oss® (small granules) + 10% collagen (porcine)
 Sizes: 50 mg (2.5 x 5.0 x 7.5 mm), 100 mg (5.0 x 5.0 x 7.0 mm),
 250 mg (7.0 x 7.0 x 7.0 mm), 500 mg (10.0 x 10.0 x 7.0 mm)


Geistlich Bio-Oss® Collagen is indicated for use in periodontal defects and extraction sockets. The 250 mg and 500 mg quantities are suitable for the treatment of larger size defects. Through the addition of collagen Geistlich Bio-Oss® Collagen can be tailored to the morphology of the defect and is particularly easy to apply.



GEISTLICH BIO-GIDE®

Bilayer collagen membrane | Sizes: 13 x 25 mm, 25 x 25 mm, 30 x 40 mm


Geistlich Bio-Gide® stabilizes the grafted area and protects bone particles from dislocation for optimal bone regeneration.⁵⁵ The natural collagen structure allows homogeneous vascularization, supports tissue integration and wound stabilization.⁵⁴ The combination of flexibility, good adhesion, and tear resistance contribute to easy handling, in turn saving time, and simplifying the surgical procedure.⁵⁶



GEISTLICH COMBI-KIT COLLAGEN

Geistlich Bio-Oss® Collagen 100 mg + Geistlich Bio-Gide® 16 x 22 mm

When used in combination, the system has optimized properties for ridge preservation and minor augmentation according to the GBR principle.



GEISTLICH MUCOGRAFT®

Collagen matrix | Sizes: 15 x 20 mm, 20 x 30 mm

Geistlich Mucograft® is a unique collagen matrix designed specifically for soft-tissue regeneration in the oral cavity. It is indicated for gaining keratinised tissue and for recession coverage. Geistlich Mucograft® provides an alternative to autologous soft-tissue grafts.

* Product availability may vary from country to country

References

- ¹ Lang NP et al., *Ann Periodontol.* 1997 Mar;2(1):343-356. (clinical study)
- ² Mombelli A et al., *Clin Oral Implants Res.* 2012 Oct;23 Suppl 6:67-76. (clinical study)
- ³ Lang NP et al., *J Clin Periodontol.* 2011 Mar;38 Suppl 11:178-181. (clinical study I)
- ⁴ Lindhe J et al., *J Clin Periodontol.* 2008 Sep;35(8 Suppl):282-285. (clinical study)
- ⁵ Mombelli A. (1994) Criteria for success. Monitoring In: *Proceedings of the first European Workshop on Periodontology*, (eds.) N.P. Lang & T. Karring, pp. 317-325. London: Quintessence. (clinical study)
- ⁶ Mombelli A. (1999) Prevention and therapy of peri-implant infections. In: *Proceedings of the 3rd European Workshop on Periodontology*, (eds.) N.P. Lang, T. Karring & J. Lindhe, pp. 281-303. Berlin: Quintessenz Verlag. (clinical study)
- ⁷ Tomasi DP & Derks J, *J Clin Periodontol.* 2012 Feb;39 Suppl 12:207-223. (clinical study)
- ⁸ Zitzmann NU & Berglundh T, *J Clin Periodontol.* 2008 Sep;35(8 Suppl):286-291. (clinical study)
- ⁹ Schwarz F & Becker J, *Peri-implant Infection: Etiology, Diagnosis and Treatment.* Quintessence Publishing. 2007. ISBN-13:978-3-938947-32-6. (clinical study)
- ¹⁰ Roos-Jansaker AM et al., *J Clin Periodontol.* 2006 Apr;33(4):290-5. (clinical study)
- ¹¹ AAP Report, *J Periodontol.* 2013 Apr;84(4):436-43. (clinical study)
- ¹² Rocchietta I, Nisand D. *J Clin Periodontol* 2012;39 (Suppl. 12):114-121. (clinical study)
- ¹³ Karoussis IK, et al. *Clin Oral Implants Res* 2003; 14: 329–39. (clinical study)
- ¹⁴ Lee C-YJ, et al., *Clin Oral Implants Res* 2012; 23: 325–33. (clinical study)
- ¹⁵ Pjetursson BE, et al., *Clin Oral Implants Res* 2012; 23: 888–94. (clinical study)
- ¹⁶ Rocuzzo M, et al., *Clin Oral Implants Res.* 2014 Oct;25(10):1105-12. (clinical study)
- ¹⁷ Heitz-Mayfield LJ, et al., *Int J Oral Maxillofac Implants* 2014; 29 (Suppl): 346–50. (clinical study)
- ¹⁸ Heitz-Mayfield LJ, Huynh-Ba G, *Int J Oral Maxillofac Implants* 2009; 24 Suppl: 39–68. (clinical study)
- ¹⁹ Strietzel FP, et al., *J Clin Periodontol* 2007; 34: 523–44. (clinical study)
- ²⁰ Bain CA, *Int J Oral Maxillofac Implants* 1996; 11: 756–59. (clinical study)
- ²¹ Serino G, Strom C, *Clin Oral Implants Res* 2009; 20: 169–174. (clinical study)
- ²² Ferreira SD, et al., *J Clin Periodontol* 2006; 33: 929–35. (clinical study)
- ²³ Wilson TG Jr, *J Periodontol* 2009; 80: 1388–92. (clinical study)
- ²⁴ Heitz-Mayfield LJ, et al., *Clin Oral Implants Res* 2004; 15: 259–68. (pre-clinical study)
- ²⁵ Lin GH, et al., *J Periodontol* 2013; 84: 1755–67. (clinical study)
- ²⁶ Costa FO, et al., *J Clin Periodontol* 2012; 39: 173–81. (clinical study)
- ²⁷ Renvert S, et al., *J Clin Periodontol* 2012; 39: 1191–97. (clinical study)
- ²⁸ Klinge B, Meyle J, Working Group 2. *Clin Oral Implants Res.* 2012 Oct;23 Suppl 6:108-10. (clinical study)
- ²⁹ Heitz-Mayfield LJ et al., *Journal of Clinical Periodontology* 2008; 35: 292–304. (clinical study)
- ³⁰ Heitz-Mayfield LJ et al., *Int J Oral Maxillofac Implants.* 2013 Aug 15. (clinical study)
- ³¹ Renvert S et al., *J Clin Periodontol.* 2008 Sep;35(8 Suppl):305-15. (clinical study)
- ³² Renvert S et al., *J Periodontol.* 2008 May;79(5):836-44. (clinical study)
- ³³ Renvert S & Giovannoli JL, *Peri-implantitis*, Quintessence International 2012, ISBN 978-2-912550-98-9 (clinical study)
- ³⁴ Claffey N et al., *J Clin Periodontol.* 2008 Sep;35(8 Suppl):316-32. (clinical study)
- ³⁵ Matarasso S et al., *Clin Oral Implants Res.* 2014 Jul;25(7):761-7. (clinical study)
- ³⁶ Romeo E et al., *Clin Oral Implants Res.* 2005 Feb;16(1):9-18. (clinical study)
- ³⁷ Romeo E et al., *Clin Oral Implants Res.* 2007 Apr;18(2):179-87. (clinical study)
- ³⁸ Schou S et al., *Int J Oral Maxillofac Implants.* 2004;19 Suppl:140-9. (clinical study)
- ³⁹ Renvert S et al., *Clin Oral Implants Res.* 2012 Oct;23 Suppl 6:84-94. (clinical study)
- ⁴⁰ Schwarz F et al., *J Clin Periodontol.* 2009 Sep;36(9):807-14. (clinical study)
- ⁴¹ Rocuzzo M et al., *Journal of Clinical Periodontology* 2011; 38: 738–45. (clinical study)
- ⁴² Roos-Jansaker A-M et al., *Journal of Clinical Periodontology* 2011; 38: 590–97. (clinical study)
- ⁴³ Froum SJ et al., *International Journal of Periodontics and Restorative Dentistry* 2012; 32: 11–20. (clinical study)
- ⁴⁴ Aghazadeh et al., *J Clin Periodontol.* 2012 Jul;39(7):666-73. (clinical study)
- ⁴⁵ Chan HL et al., *J Periodontol.* 2014 Aug;85(8):1027-41. (clinical study)
- ⁴⁶ Schwarz F et al., *J Clin Periodontol.* 2010 May;37(5):449-55. (clinical study)
- ⁴⁷ Schwarz F et al., *J Clin Periodontol.* 2006 Jul;33(7):491-9. (clinical study)
- ⁴⁸ Schwarz F et al., *J Clin Periodontol.* 2008 Jan;35(1):80-7. (clinical study)
- ⁴⁹ Schwarz F et al., *Clin Oral Implants Res* 2014; 25(1): 132–36. (clinical study)
- ⁵⁰ Schwarz F et al., *Int J Periodontics Restorative Dent* 2014; 34(4): 489–95. (clinical study)
- ⁵¹ Derks J et al., *J Clin Periodontol* 2015;42 (Suppl.16):158-171. (clinical)
- ⁵² Salvi GE & Zitzmann NU, *Int J Oral Maxillofac Implants.* 2014;29 Sppl:292-307. (clinical study)
- ⁵³ Schwarz F et al., *J Clin Periodontol* 2009; 36:807-814. (clinical study) 54 Rothamel D et al. *Clin. Oral Implants Res.* 2005; 16(3): 369-378. (pre-clinical study)
- ⁵⁵ Perelman-Karmon M et al. *Int J Periodontics Restorative Dent.* 2012 Aug;32(4):459-65. (clinical study)
- ⁵⁶ Data on File. Geistlich Pharma AG, Wolhusen, Switzerland. (pre-clinical study)

Additional source of the content of this brochure are articles published in “Geistlich News, Volume 7; Issue 2, 2014”. Articles cited with the courtesy of Prof. Niklaus P. Lang, Prof. Giovanni E. Salvi, Prof. Lisa J. A. Heitz-Mayfield, Prof. Frank Schwarz, Prof. Andrea Mombelli.



More details about our
distribution partners:
www.geistlich-biomaterials.com

Manufacturer

Geistlich Pharma AG
Business Unit Biomaterials
Bahnhofstrasse 40
6110 Wolhusen, Switzerland
Phone +41 41 492 55 55
Fax +41 41 492 56 39
www.geistlich-biomaterials.com

Affiliate Australia and New Zealand

Geistlich Pharma Australia Pty Ltd.
The Zenith – Tower A
Level 21, Suite 21.01
821 Pacific Highway
NSW 2067 Chatswood, Australia
Phone +61 1800 776 326
Fax +61 1800 709 698
info@geistlich.com.au
www.geistlich.com.au

Affiliate Great Britain and Ireland

Geistlich Sons Limited
1st Floor, Thorley House
Bailey Lane
Manchester Airport
Manchester M90 4AB, Great Britain
Phone +44 161 490 2038
Fax +44 161 498 6988
info@geistlich.co.uk
www.geistlich.co.uk

Affiliate North America

Geistlich Pharma North America Inc.
202 Carnegie Center
Princeton, NJ 08540 USA
Phone +1 855 799 5500
info@geistlich-na.com
www.geistlich-na.com

Distribution Canada

HANSAmEd Ltd.
2830 Argentia Road
Unit 5-8
L5N 8G4 Mississauga, Canada
Phone +1 800 363 2876
Fax +1 800 863 3213
orders@hansamed.net
www.hansamed.net