

Postero-lateral Osteochondral Injury of the Talus: AMIC® with Autologous Bone Grafting



Dr. María Carmen Blasco Mollá

Dr. María Carmen Blasco Mollá is a specialist in Orthopedic Surgery and Traumatology in the Foot and Ankle Department of the University Clinical Hospital of Valencia, Spain. She is an Associate Professor in the Department of Surgery at the University of Valencia, Spain.



Dr. Francisco Forriol Brocal

Dr. Francisco Forriol Brocal is a specialist in Orthopedic Surgery and Traumatology in the Foot and Ankle Department of the University Clinical Hospital of Valencia, Spain. He is the Head of the Specialized Health Training Studies at the University Clinical Hospital of Valencia, Spain.

Clinical Problem

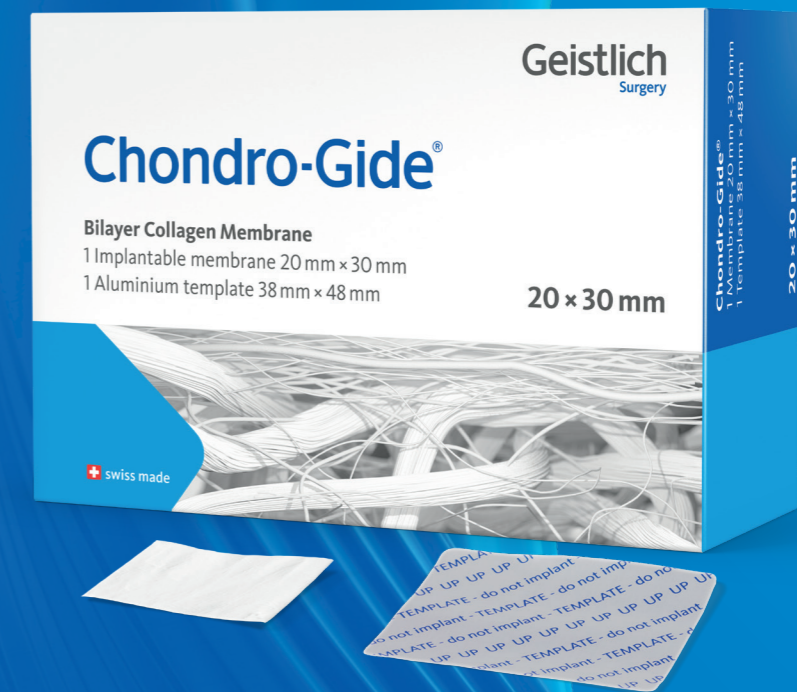Surgical management of osteochondral lesions (OCL) can be challenging due to the accessibility of the lesion. When the size of the osteochondral lesion (OCL) exceeds 1 cm², matrix-augmented bone marrow stimulation techniques (m-BMS) such as AMIC® Chondro-Gide® are recommended.



For further information:
www.geistlich-ortho.com

Geistlich Pharma AG
Bahnhofstrasse 40
CH-6110 Wolhusen
www.geistlich-ortho.com

AMIC® Chondro-Gide®: The one-step cartilage therapy with the best evidence¹



¹ Walther et al. 2024: Operative management of osteochondral lesions of the talus: 2024 recommendations of the working group 'clinical tissue regeneration' of the German Society of Orthopedics and Traumatology (DGOU)

Postero-lateral Osteochondral Injury of the Talus: AMIC® with Autologous Bone Grafting

Clinical Problem

Patient History

A 63-year-old man presented with progressively worsening left ankle pain following a fall from a height of two meters. Symptoms first appeared one year after the trauma. The clinical examination revealed that the patient had pain on palpation with preserved active and passive mobility of the ankle. The ankle was painful during walking and especially when going up- and downstairs. The preoperative AOFAS score was 48.

Preoperative Imaging

Preoperative load-bearing radiographs show the lateral osteochondral lesion of the left talus and the subchondral bone cysts on either side of the lesion (fig. 1 and 2).

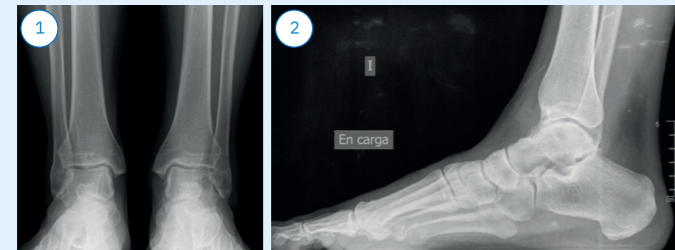


Fig. 1 and 2: preoperative weight-bearing radiographs

CT scans show the multicystic lesion in the lateral part of the talus and small free intra-articular bodies in its most lateral and posterior region. Anteriorly, a subcortical fracture line of approximately 12 mm in transverse and 10 mm in anteroposterior dimension is visualized. Osteophytes are seen in the anterior region of the distal tibial epiphysis (fig. 3, 4 and 5).

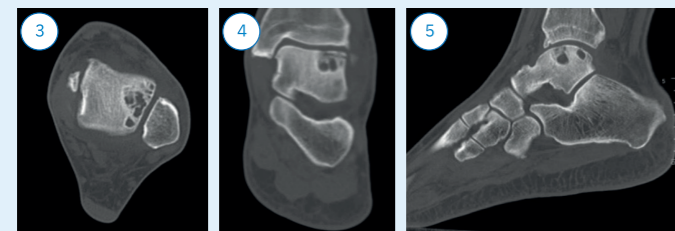


Fig. 3, 4 and 5: preoperative CT scans

The preoperative MRI shows a developed transchondral lesion in the entire lateral slope of the talar dome measuring 20x14 mm, probably subacute in nature with bone edema and indications of changes in the subcortical bone (fig. 6 and 7).

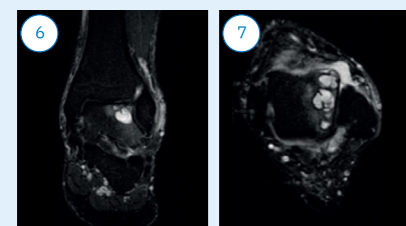


Fig. 6 and 7: the preoperative MRI

Treatment

Treatment

The surgery starts with an arthroscopy using anteromedial and antero-lateral portals to confirm the location and the size of the OCL and to rule out other concomitant lesions. There were no signs of ankle instability, neither clinically nor from previous preoperative tests.

After arthroscopy was completed, a supplement was added in the left gluteal area to achieve internal rotation of the left lower extremity, which allowed for better lateral access to the ankle joint.

To surgically access the ankle joint, a lateral longitudinal incision at the midline of the fibula with distal extension anteriorly was made.

After locating the level of the articular surface of the talus with a scan, a Y-shaped osteotomy was performed opposite the fibula. It is important to locate the optimal level of the osteotomy to access the OCL in the lateral region of the talus by associating a forced varus maneuver of the same (fig. 8). The ligaments of the distal tibiofibular syndesmosis should be preserved.

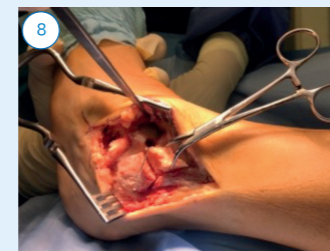


Fig. 8: osteotomy of the fibula for access to the lateral region of the talus

The cartilage lesion was characterized by typical signs of an irregular surface with changes in intensity and brightness compared to healthy cartilage as well as softening when compressed with a probe. The edges of the lesion were marked with a scalpel and a proper defect debridement was performed, including the resection of an osteochondral fragment (fig. 9).

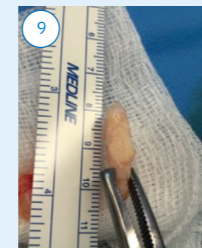


Fig. 9: sample of the resected osteochondral fragment

Bone marrow stimulation was performed with a 1.2mm drill bit to facilitate blood supply from the healthy cancellous bone (fig. 10). Precautions were taken to avoid iatrogenic rupture of the lateral wall of the cyst, which generally is thin and friable.

Treatment

The depth of the resulting OCL cavity was assessed to calculate the amount of cancellous bone needed to fill it.

Autologous cancellous bone was harvested from the ipsilateral iliac crest. The autologous bone was introduced into the debrided, cystic cavity with a spoon and impacted with a blunt instrument, leaving a space of about 2 mm up to the theoretical surface of the lesion (fig. 11).

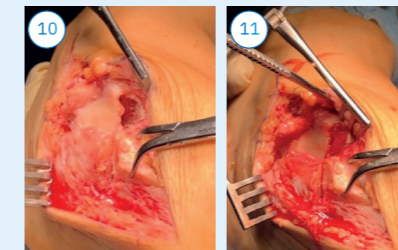


Fig. 10: debrided OCL Fig. 11: filled defect with microdrillings

The Chondro-Gide® membrane was cut to the shape and the size of the defect. The membrane was marked with a sterile marker on the upper, dense side and implanted into the defect with the rough side facing the prepared bone bed (fig. 12). The Chondro-Gide® membrane should be approximately 1 mm below the level of the healthy perilesional cartilage to avoid protrusion after its hypertrophy.

The interface between the Chondro-Gide® membrane and the surrounding cartilage was sealed with fibrin glue. After 5–6 minutes, gentle passive flexion-extension movements of the ankle joint were performed to adapt the convex geometry of the Chondro-Gide® membrane to the concavity of the distal tibial articular surface and to check the stability of the membrane.

Reduction and osteosynthesis of the osteotomy with a screw-retained, anatomical lateral plate and antero-lateral oblique compression screws were done (fig. 13). The anterior talofibular ligament was reattached with a resorbable anchoring system.

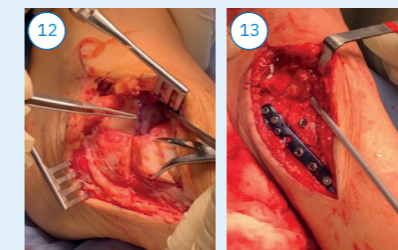


Fig. 12: the implanted Chondro-Gide® Fig.13: the osteosynthesis with an anatomical plate

Follow-Up

Follow-up and Postoperative Treatment

No drain was used, and an initial splint dressing was applied in a functional position until the wounds healed.

The patient was examined 15 days after surgery and the splint bandage was replaced with a walker-type orthosis with the ankle joint in a functional position.

The patient began partial weight bearing of the left lower extremity with crutches two months after surgery. Active and passive flexion and extension of the operated ankle joint were indicated from the moment the initial splint bandage was removed.

Full weight bearing with the orthosis was indicated three months after surgery.

At the 6-month follow-up, mild discomfort and slight swelling of the left ankle persisted.

At the 1-year and 3-year follow-up visits, the patient was asymptomatic and satisfied with the result of the procedure (fig. 14). He had begun low-intensity sports without pain. Full active ankle range of motion was possible. The 3-year postoperative AOFAS score was 97. The patient experienced no discomfort from the implanted osteosynthesis material and refused its removal.

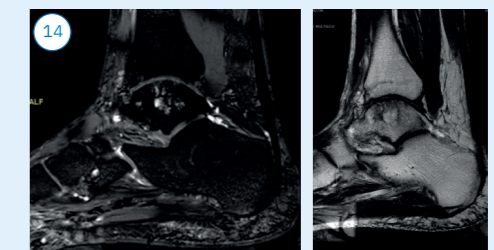


Fig. 15: cartilage gradient MRI 3 years postoperatively. Signs of restoration of the articular surface are seen in the injured area, with persistence of a cystic image in the subchondral bone.