

BioBrief

Extraction Sockets

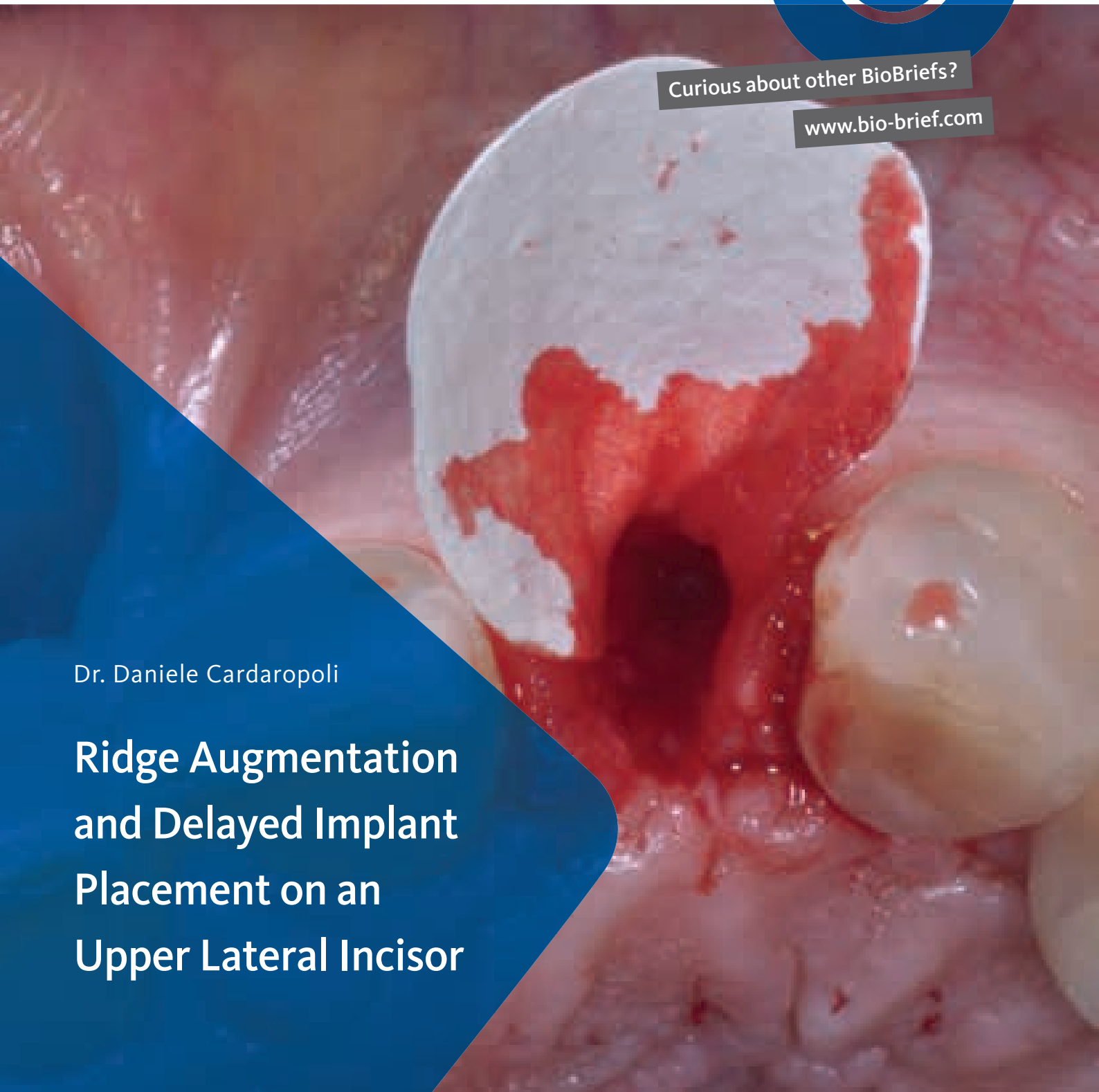

Curious about other BioBriefs?

www.bio-brief.com

Dr. Daniele Cardaropoli

**Ridge Augmentation
and Delayed Implant
Placement on an
Upper Lateral Incisor**



The Situation

An adult female patient presented with an endodontic/prosthetic failure on the maxillary left lateral incisor. The patient's request was to have a definitive implant-supported single crown. The clinical situation revealed recession of the free gingival margin, while the CBCT evaluation showed the missing buccal bone plate, which contra-indicated an

immediate implant placement. The treatment plan included a staged approach with a ridge augmentation procedure at the time of tooth extraction, in order to recreate the buccal bone plate and reduce the gingival recession. By moving the free gingival margin, keratinized tissue was gained through an open-healing approach.

The Risk Profile

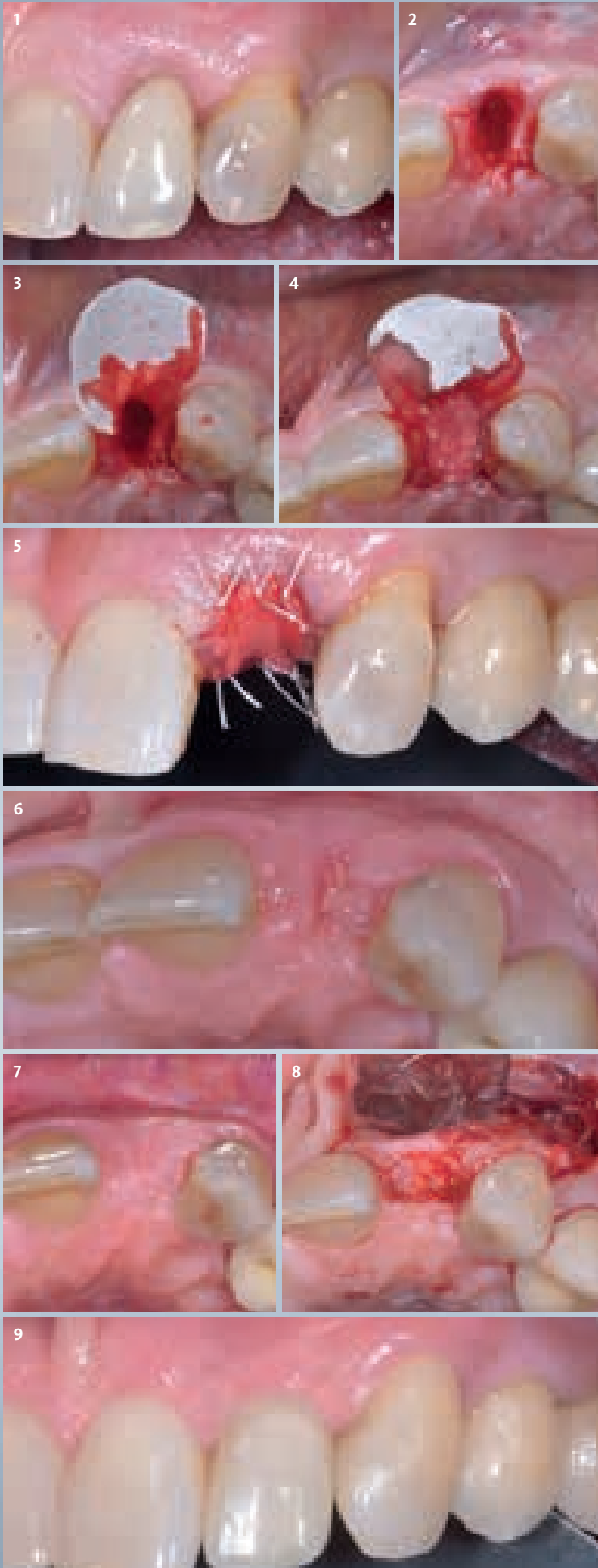
	Low Risk	Medium Risk	High Risk
Patient's health	Intact immune system	Light smoker	Impaired immune system
Patient's esthetic requirements	Low	Medium	High
Height of smile line	Low	Medium	High
Gingival biotype	Thick – "low scalloped"	Medium – "medium scalloped"	Thin – "high scalloped"
Shape of dental crowns	Rectangular		Triangular
Infection at implant sight	None	Chronic	Acute
Bone height at adjacent tooth site	≤ 5 mm from contact point	5.5 - 6.5 mm from contact point	≥ 7 mm from contact point
Restorative status of adjacent tooth	Intact		Compromised
Width of tooth gap	1 tooth (≥ 7 mm)	1 tooth (≤ 7 mm)	2 teeth or more
Soft-tissue anatomy	Intact		Compromised
Bone anatomy of the alveolar ridge	No defect	Horizontal defect	Vertical defect

Note: The compromised soft-tissue created a high risk situation for esthetic failure and the need for a staged approach, in order to coronalize the free gingival margin

"The patient had a failing crown with compromised soft-tissue and requested a single crown rehabilitation with improved esthetics.,,"



Daniele Cardaropoli, Dds – Torino, IT Periodontist – PROED, Institute for Professional Education in Dentistry, Torino
 Doctor of Dentistry and Certificate in Periodontology from the University of Torino, Italy. Active member of the Italian Society of Periodontology, European Federation of Periodontology, Italian Academy of Osseointegration and Academy of Osseointegration. International member of the American Academy of Periodontology. Scientific Director of Institute for Professional Education in Dentistry (PROED), Torino. Member of the Editorial Board of The International Journal of Periodontics and Restorative Dentistry. Private practice in Torino, Italy.



The Approach

The treatment goals were to improve the soft-tissue levels and regenerate the buccal bone plate. After performing a flapless extraction procedure, a specifically designed resorbable bilayer collagen membrane, Geistlich Bio-Gide® Shape, was inserted into the socket with the long wing in contact with the buccal surface and the smooth, compact upper layer facing outward. The alveolus was then grafted with Geistlich Bio-Oss® Collagen. The three smaller wings of the membrane were folded on top of the graft material and sutured to the surrounding soft-tissue, allowing for open-healing.

The Outcome

This case demonstrates how it is possible to **improve the clinical and esthetic situation** that was presented at baseline. Despite missing the buccal bone plate and the recession of the free gingival margin, the ridge augmentation procedure performed with the combination of **Geistlich Bio-Gide® Shape and Geistlich Bio-Oss® Collagen** was able to create a **positive volume of the ridge**, allowing for a prosthetically guided implant placement.



Click or Scan to
access the webinar

- | 1 Baseline: endodontic/prosthetic failure on the maxillary left lateral incisor.
- | 2 Clinical situation following a minimally invasive, flapless extraction approach.
- | 3 Geistlich Bio-Gide® Shape is inserted with the long wing in contact with the buccal surface in order to recreate the cortical bone.
- | 4 The socket is carefully grafted with Geistlich Bio-Oss® Collagen.
- | 5 The three remaining wings are folded over the bone graft and gently secured inside the gingival sulcus.
- | 6 4 weeks post-operative view with an open-healing approach, showing a positive soft-tissue response.
- | 7 Implant placement can be planned 4 months after the ridge augmentation procedure.
- | 8 After flap elevation at 4 months showing, the new buccal bone plate together with a completely filled alveolus.
- | 9 Final ceramic crown one year after tooth extraction shows an esthetic improvement when compared with the baseline image.



More details about our
distribution partners:
www.geistlich-biomaterials.com

Manufacturer

Geistlich Pharma AG
Business Unit Biomaterials
Bahnhofstrasse 40
6110 Wolhusen, Switzerland
Phone +41 41 492 55 55
Fax +41 41 492 56 39
www.geistlich-biomaterials.com

**Affiliate Australia and
New Zealand**

Geistlich Pharma Australia
and New Zealand
The Zenith – Tower A
Level 19, Suite 19.01
821 Pacific Highway
NSW 2067 Chatswood, Australia
Phone +61 1800 776 326
Fax +61 1800 709 698
info@geistlich.com.au
www.geistlich.com.au

**Affiliate Great Britain
and Ireland**

Geistlich Sons Limited
1st Floor, Thorley House
Bailey Lane
Manchester Airport
Manchester M90 4AB, Great Britain
Phone +44 161 490 2038
Fax +44 161 498 6988
info@geistlich.co.uk
www.geistlich.co.uk

Affiliate North America

Geistlich Pharma North America Inc.
202 Carnegie Center
Princeton, NJ 08540 USA
Phone toll-free +1 855 799 5500
info@geistlich-na.com
www.geistlich-na.com

Distribution Canada

HANSAmEd Ltd.
2830 Argentia Road
Unit 5-8
L5N 8G4 Mississauga, Canada
Phone +1 800 363 2876
Fax +1 800 863 3213
orders@hansamed.net
www.hansamed.net



Keys to Success

Minimally invasive, flapless extraction

Immediately grafting the fresh extraction socket with
Geistlich Bio-Oss® Collagen

Protection of the bone substitute material with
Geistlich Bio-Gide® Shape

Proper adaptation of Geistlich Bio-Gide® Shape on the buccal
surface of the alveolus

Open-healing capability of Geistlich Bio-Gide® Shape

Prosthetically driven implant placement



Ridge augmentation combining the use of Geistlich
Bio-Oss® Collagen and Geistlich Bio-Gide® Shape is a
predictable minimally invasive regenerative
procedure able to create sufficient ridge volume suitable
for prosthetically driven implant placement.

